ALTERACIONES HEPÁTICAS TUMORALES

EPITELIALES

- BENIGNOS
  - ADENOMA
  - HIPERPLASIA NODULAR FOCAL
  - HIPERPLASIA NODULAR REGENERATIVA
- MALIGNOS
  - HEPATOBLASTOMA
  - HEPATOCARCINOMA
  - METASTASIS

MESENQUIMATOSOS

- BENIGNOS
  - HAMARTOMA MESENQUIMAL
  - HEMANGIOMA
  - HEMANGIOENDOTELIOMA I
  - PSEUDOTUMOR INFLAMATORIO
  - ANGIOMIOLIPOMA
- MALIGNOS
  - SARCOMA EMBRIONARIO
  - ANGIOSARCOMA
  - HEMANGIOENDOTELIOMA II
  - TUMOR FUSOCELULAR

HIPERPLASIA NODULAR FOCAL

- BENIGNO
- NO ES ESTRICTAMENTE NEOPLASIA (TUMOR)
- CICATRIZ ESTELAR
- USO DE ESTEROIDES AO
- TRASTORNO VASCULAR QUE AFECTA LA REMODELACIÓN HEPÁTICA
- HISTOLOGÍA NO CARACTERÍSTICA

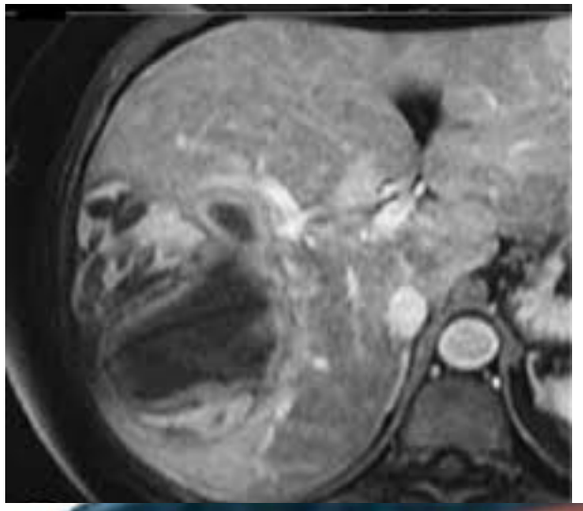

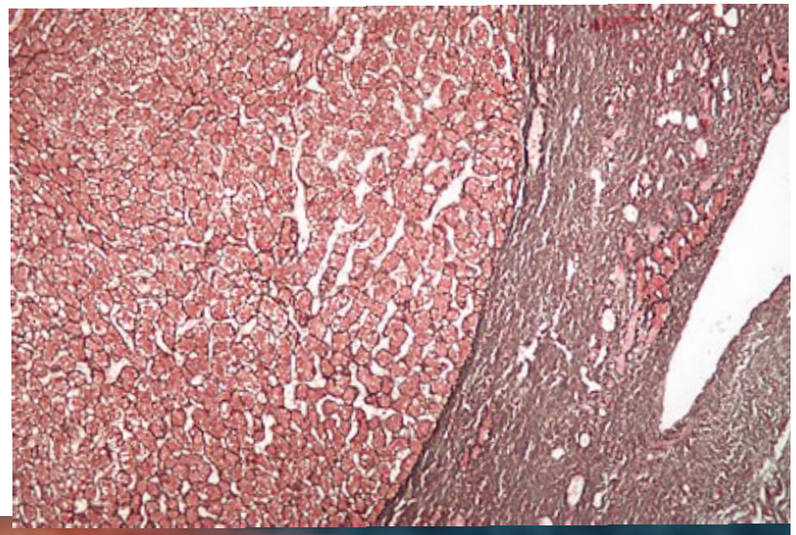

HAMARTOMA MESENQUIMAL

- EN NIÑOS (<2 AÑOS)
- 70% HOMBRES
- PUEDEN SER MUY GRANDES
- AREAS QUÍSTICAS O PSEUDOQUÍSTICAS
- CELULAS MESENQUIMATOSAS INMADURAS
- ESTROMA LAXO EDEMATOSO
- DESORGANIZACIÓN
- RESECCIÓN QX CURATIVA
- EXCEPCIONALMENTE — SARCOMA EMBRIONARIO

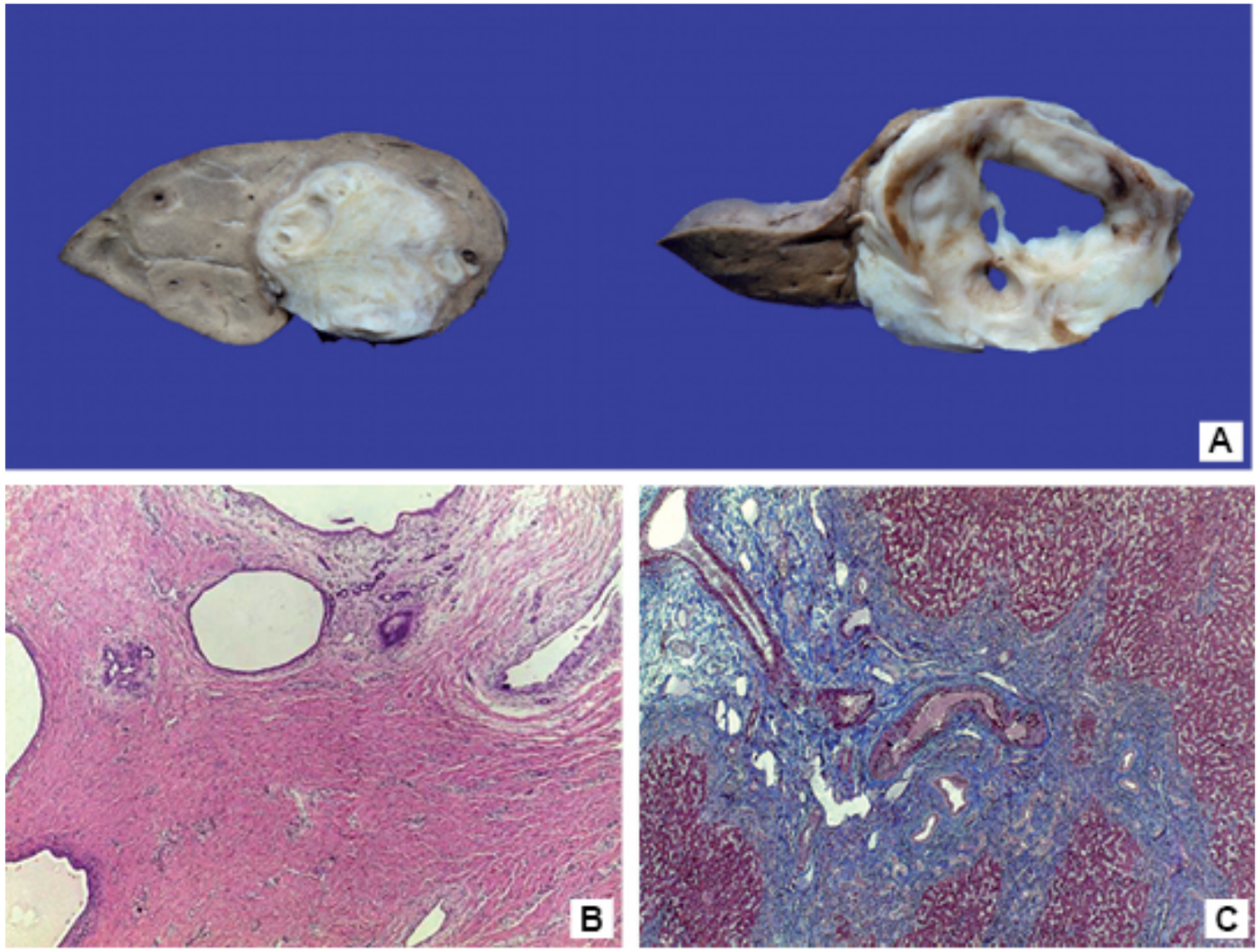

HEMANGIOMA

- FRECUENTES
- ASINTOMÁTICOS
- CUALQUIER EDAD
- 90% ÚNICOS
- 4 A 20 CM (LA MAYORÍA PEQUEÑOS)
- BIEN DELIMITADOS
- HISTOLOGÍA DE HEMANGIOMA
- Hemangioma endotelioma infantil
  - <1 año, 33% 1er mes de vida, 2:1 M:H, ruptura es grave e IC, algunos con mtts y muerte —- hemangioendoteliomas tipo II

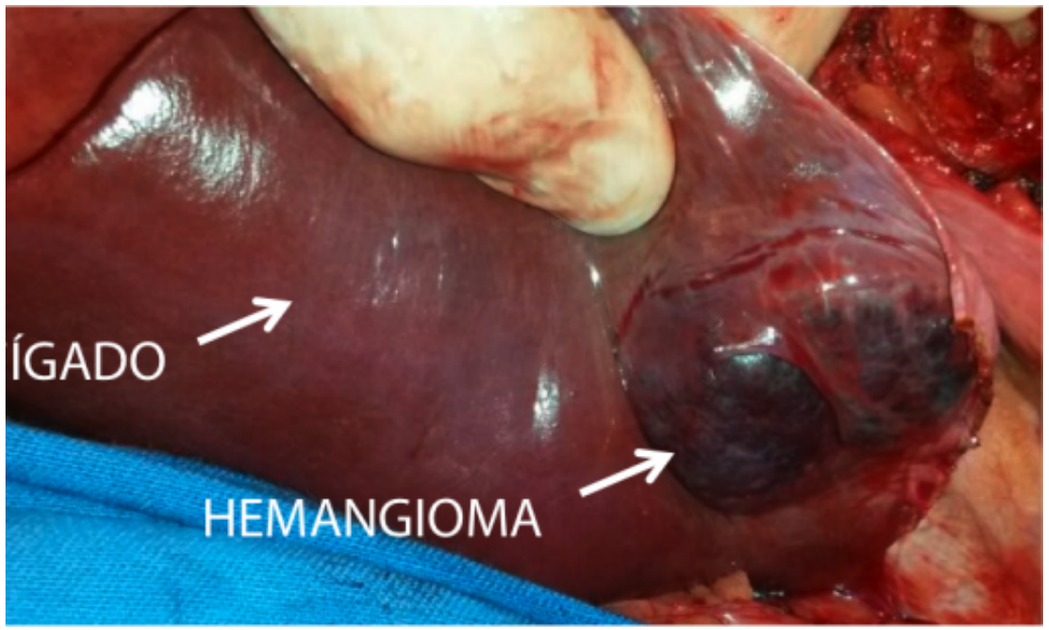

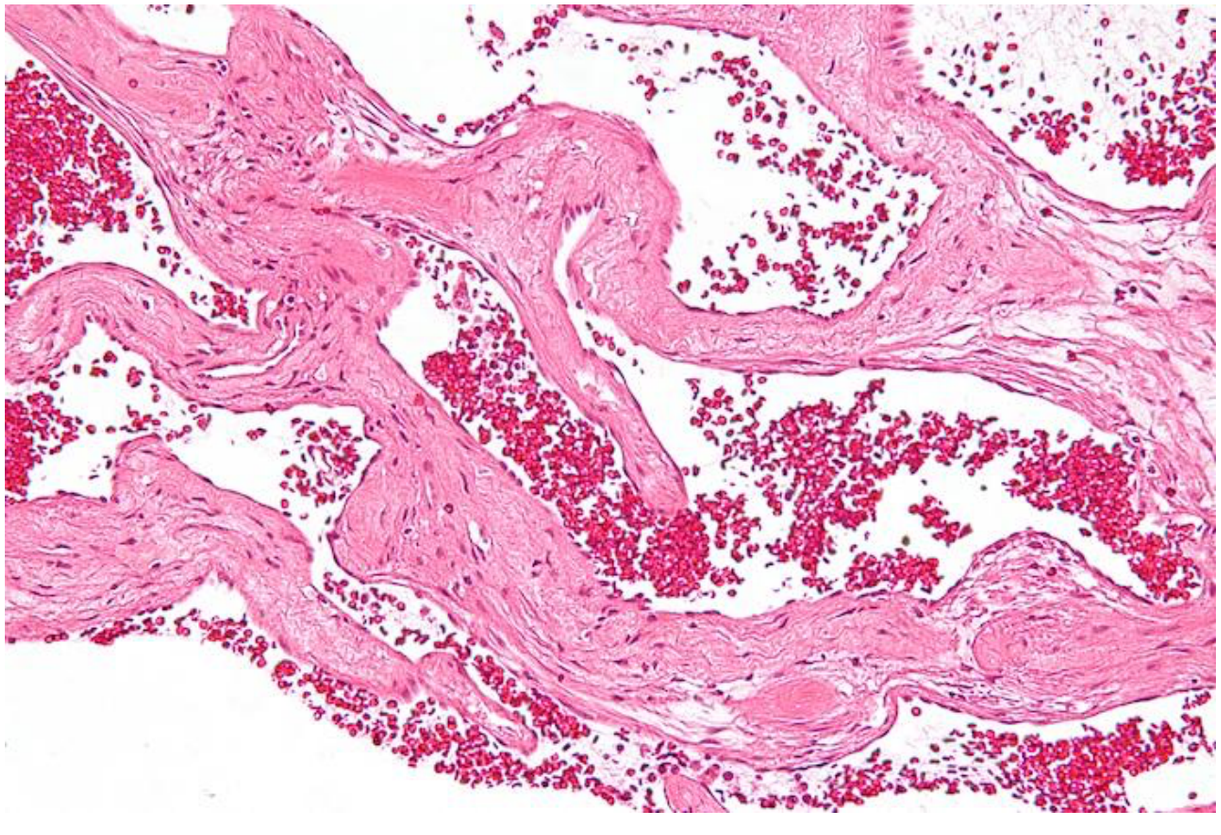

HEPATOBLASTOMA

- EDAD PEDIATRICA (<5 AÑOS)
- SEMEJA DIVERSAS ETAPAS DEL DESARROLLO HEPATOCELULAR
- ACOMPAÑA DE OTROS ELEMENTOS
- ASOCIADO A OTRAS ENF CONGENITAS
  - SD. BECKWITH-WIDEMANN
  - POLIPOSIS COLÓNICA CINENITA FAMILIAR
- MUTACIONES AX1N1, bCATENINA, p53
- MACRO: MASAS GRANDES BIEN DELIMITADAS, LOBULADOS, HETEROGÉNEOS
- MICRO:
  - EPITELIAL
    - FETAL
    - EMBRIONARIO
    - MACROTRANSVESICULAR
    - CÉLULAS PEQ INDIFERENCIADO
  - MESENQUIMATOSO (HEMATOPOYESIS ABUNDANTE)
  - MIXTO
- TRATAMIENTO QX + QT

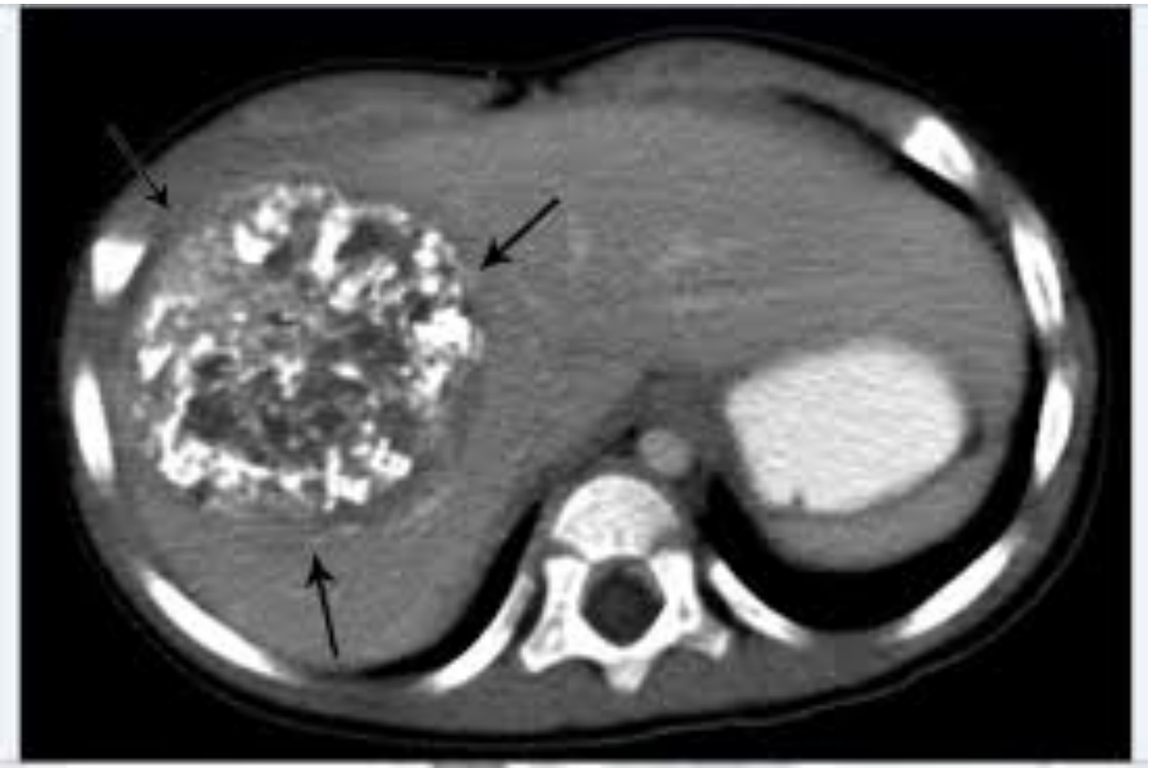

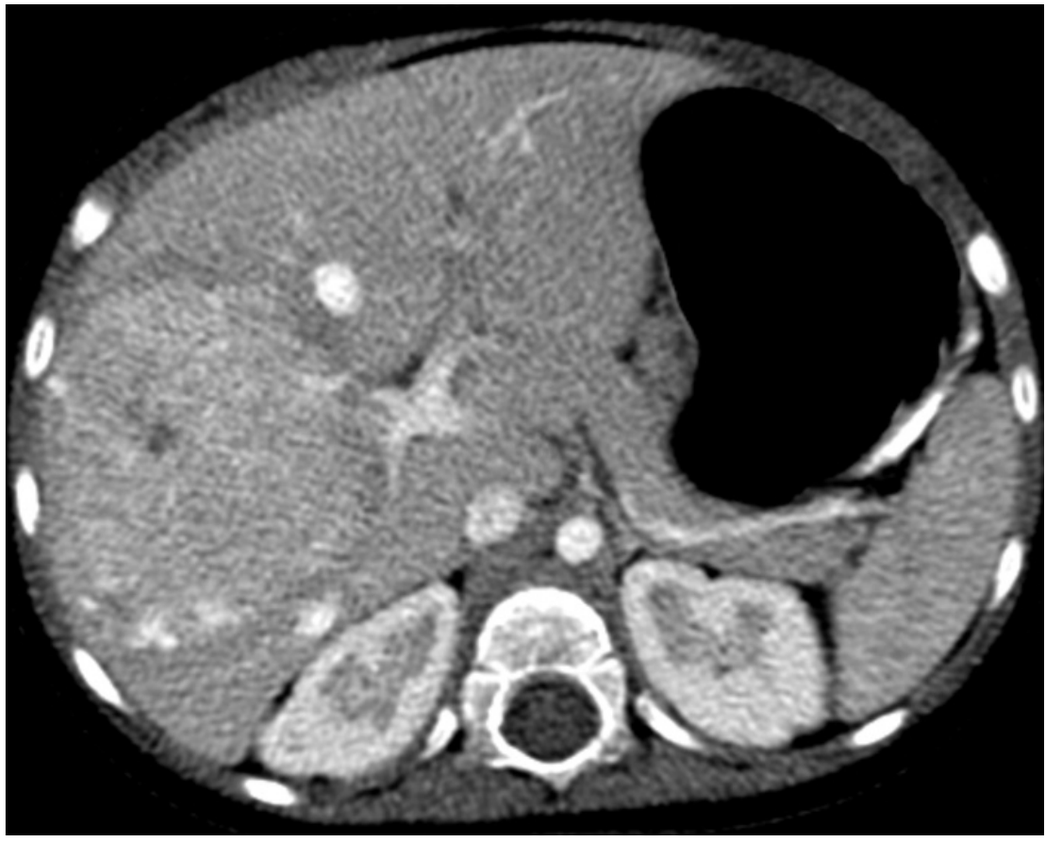

cm
1
2
3
CHU
Sainte-Justine
Le centre hospitalier
universitaire mère-enfant

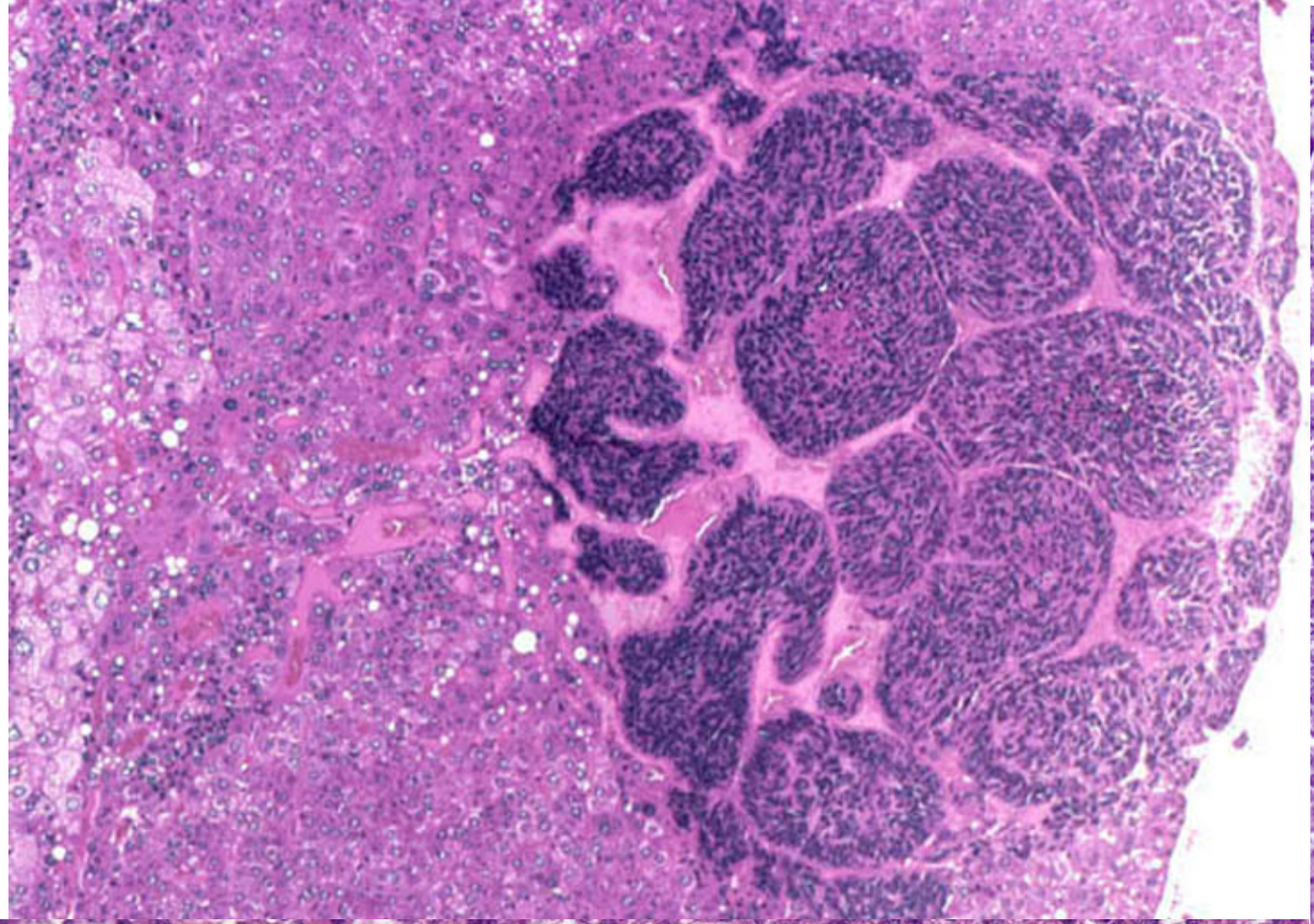

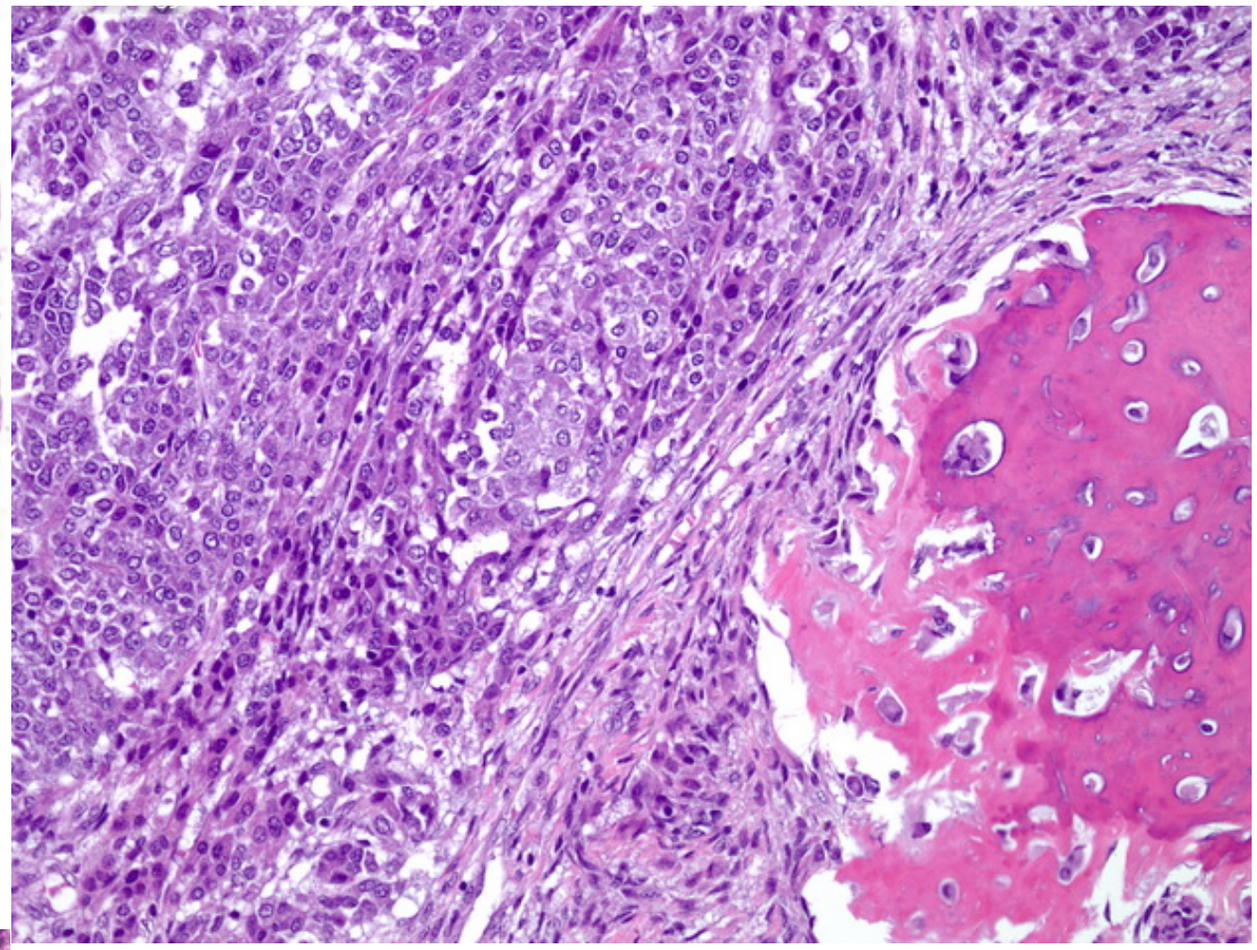

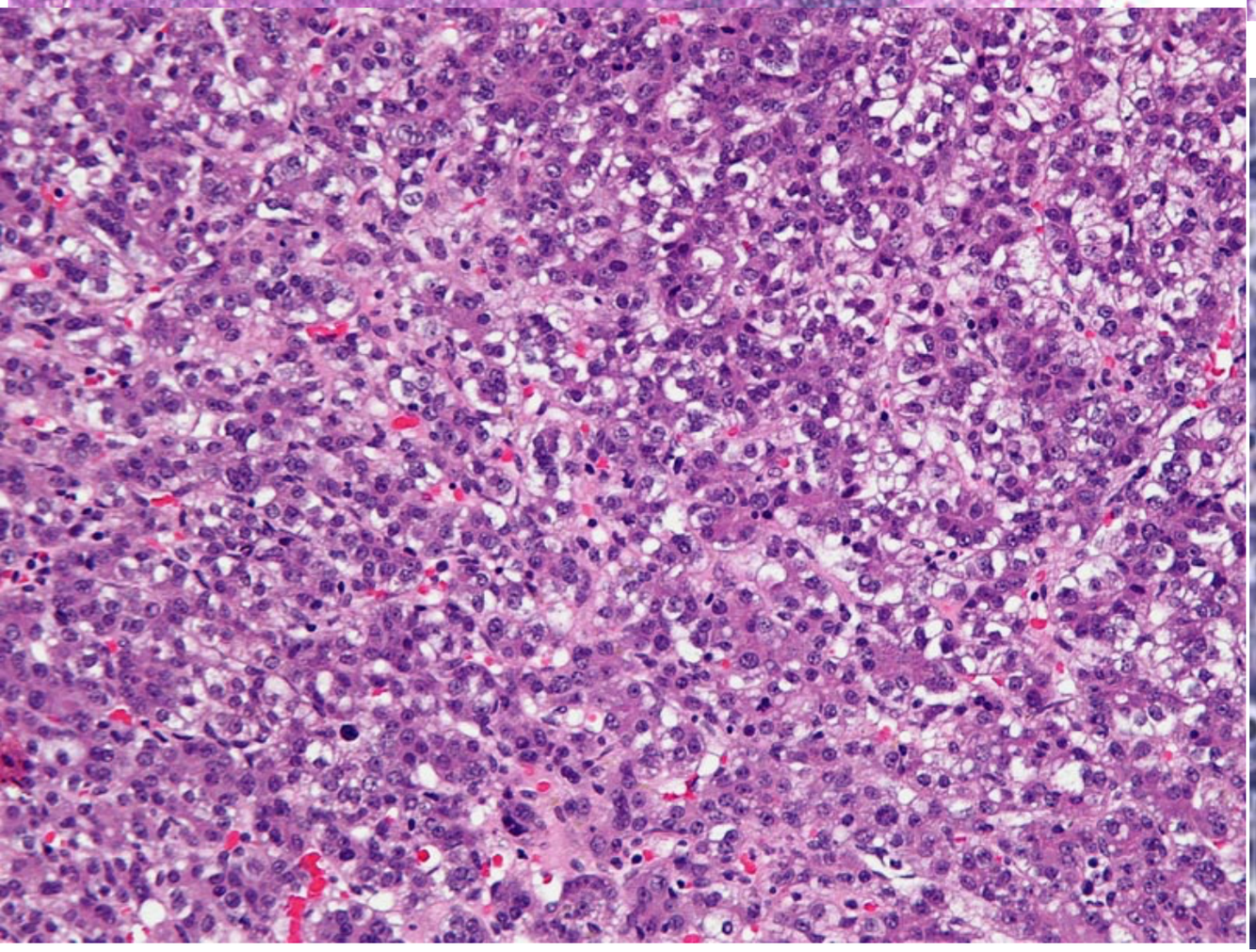

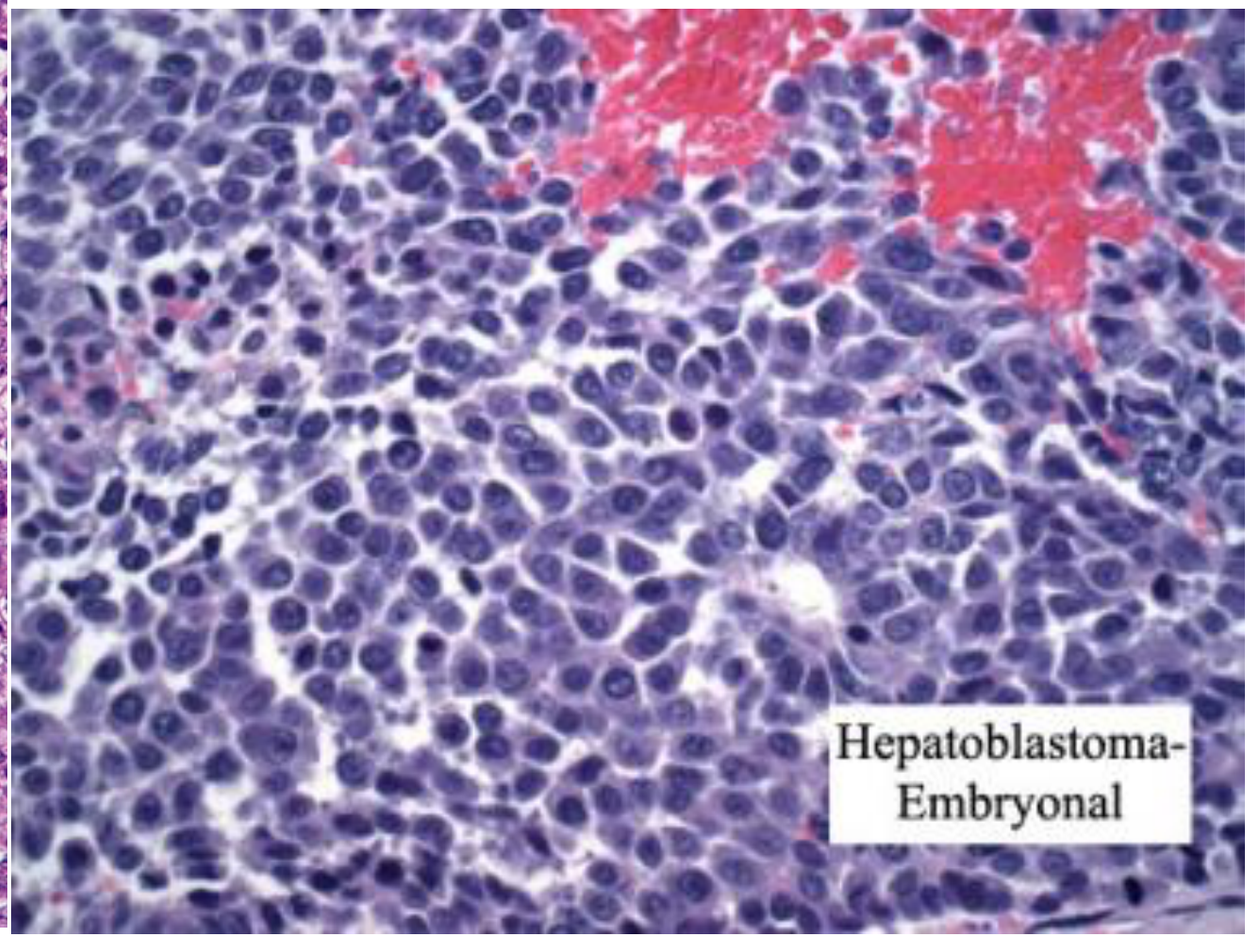
Hepatoblastoma-
Embryonal

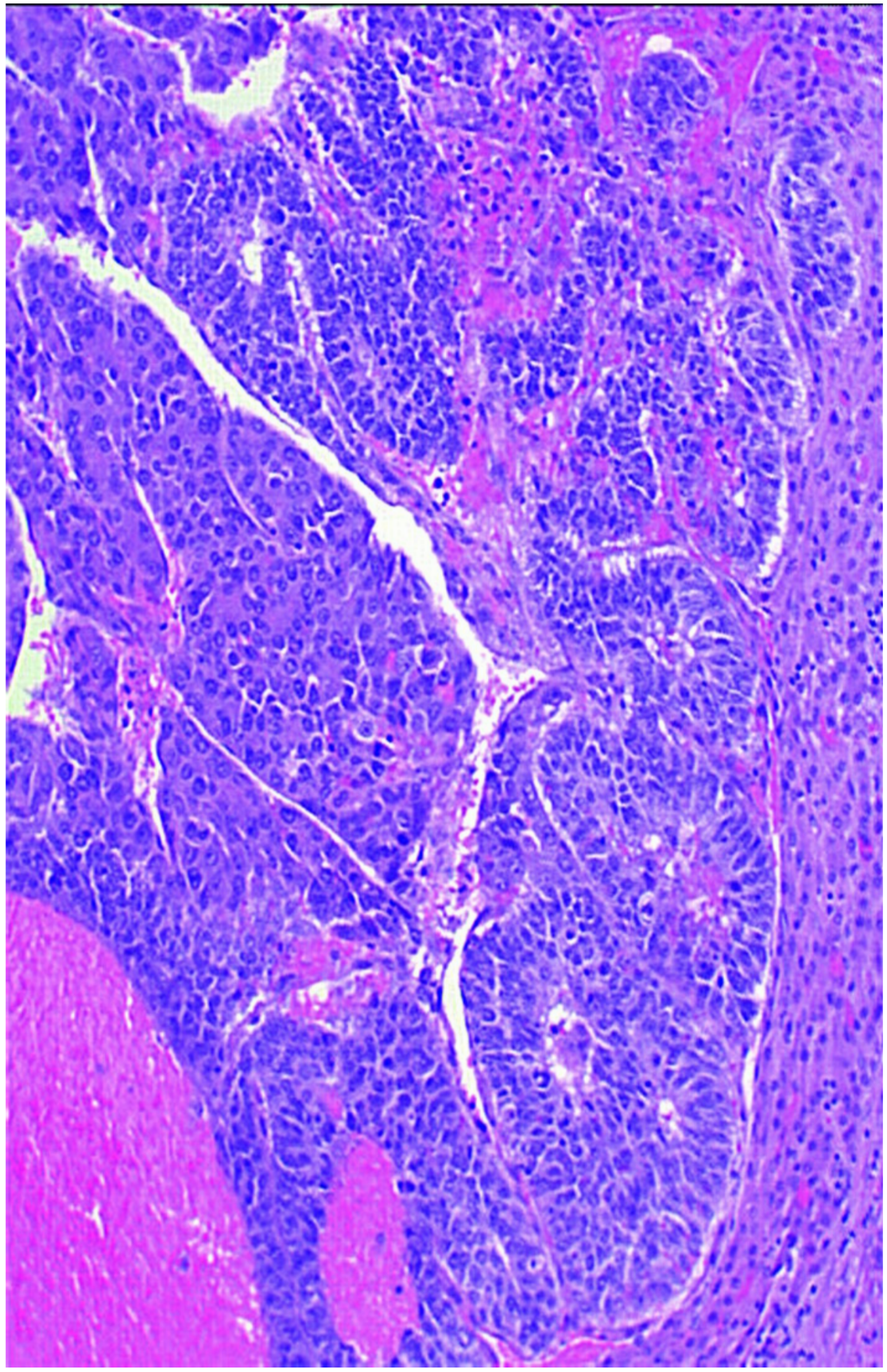

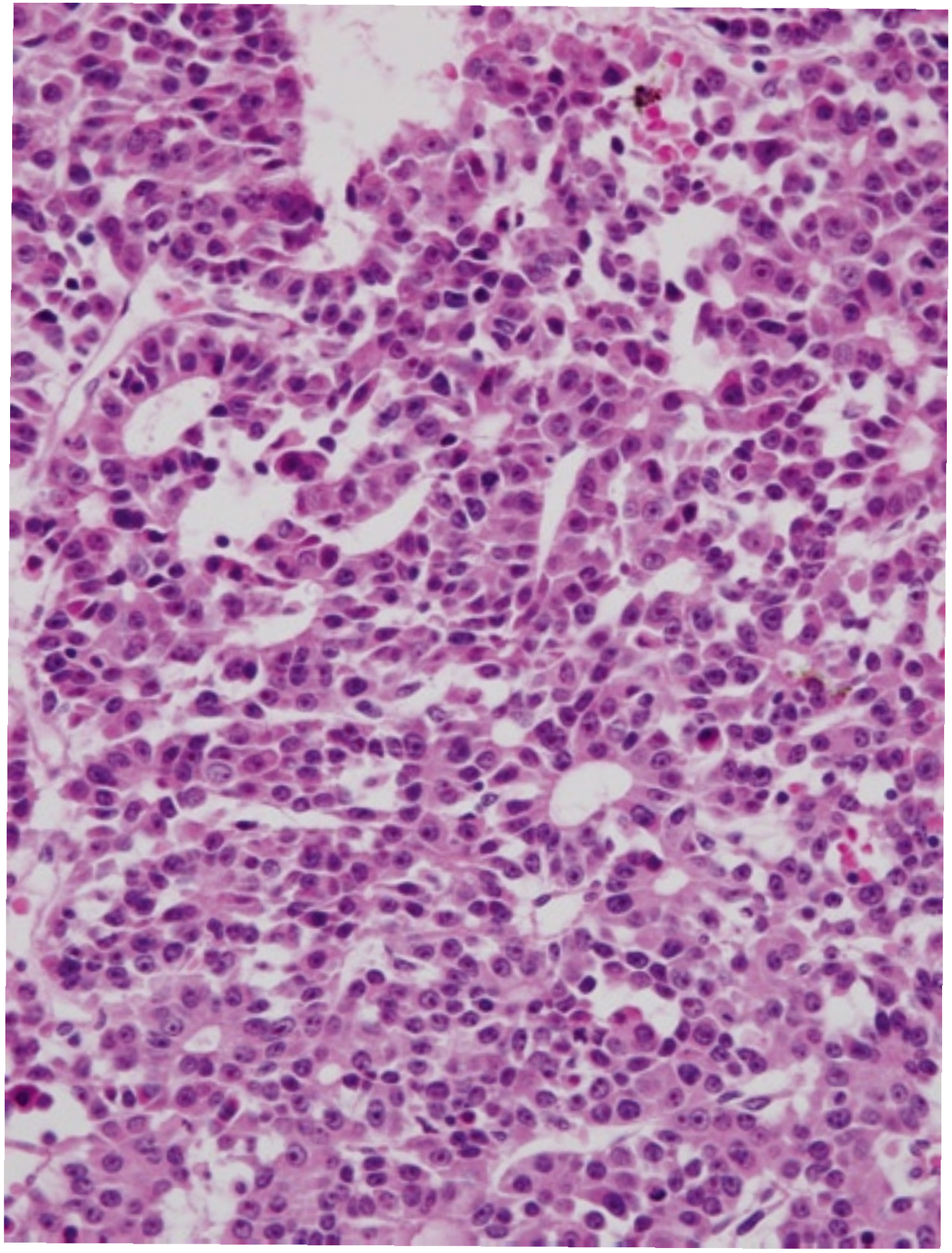

HEPATOCARCINOMA

- ORIGEN EN HEPATOCITOS
- MAS COMUN ADULTOS
- EPIDEMIOLOGIA PARALELA A LA DISTRICBUCIÓN GEOGRÁFICA DE LA HEPATITIS B
- DAÑO CRÓNICO HEPÁTICO RELACIÓN A SU DESARROLLO
- MUTACION: AX1N1, p53, 2LOH, bCATENINA, OTRAS
- MUY AGRESIVO, SV 3 Meses- 1 AÑO
- MASA GRANDE CON NÓDULOS SATELITES O MULTIPLES NÓDULOS
- MICRO DESDE BIEN A POCO DIFERENCIADO TANTO MORFOLOGÍA CELULAR COMO ARQUITECTURA
- IHQ HASTA 100 ANTÍGENOS - HSA (HepAr1), aFetoproteína, a1 antitripsina, CAM5.2, EMA, WT-1 citoplasmatica.

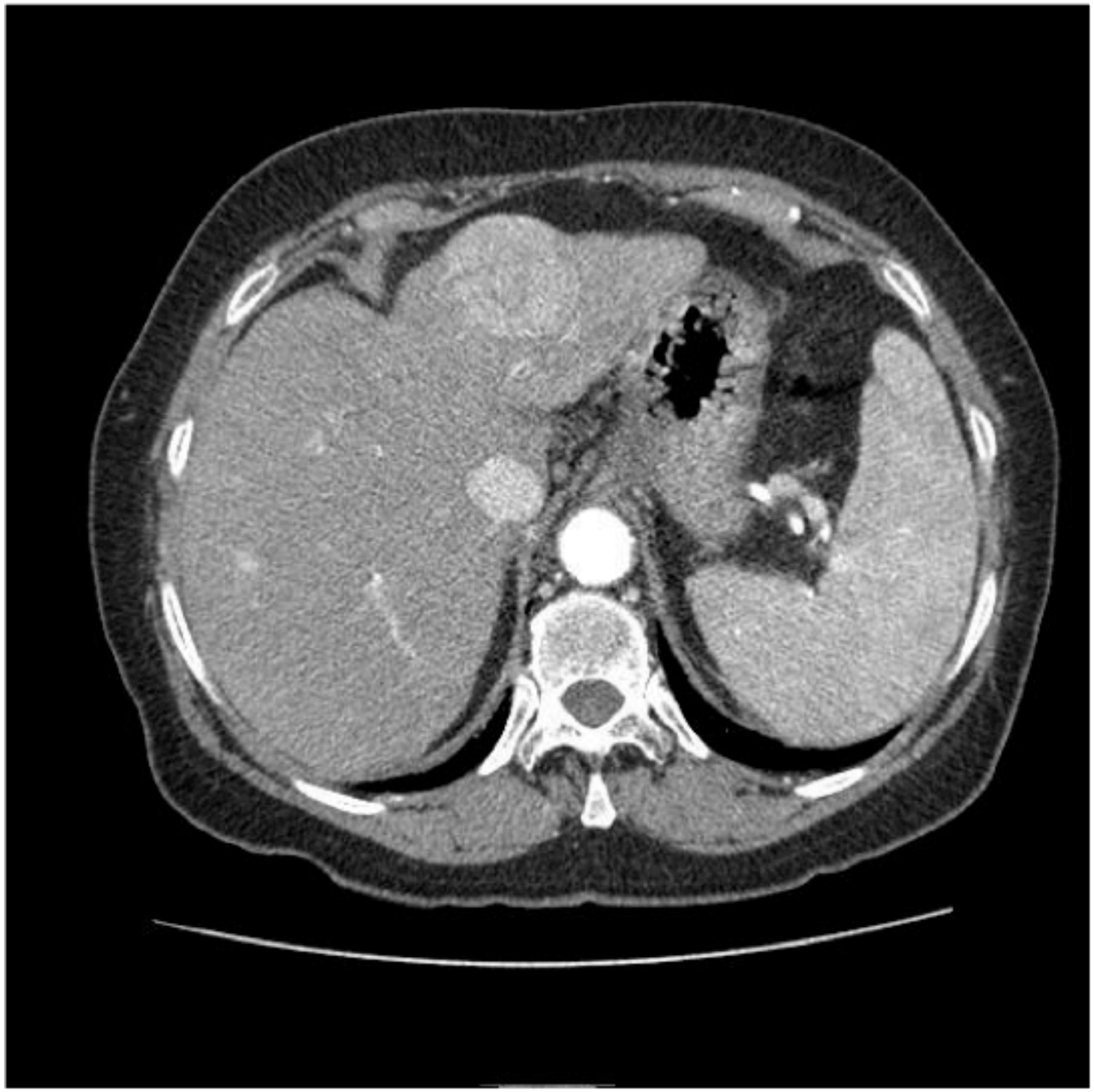

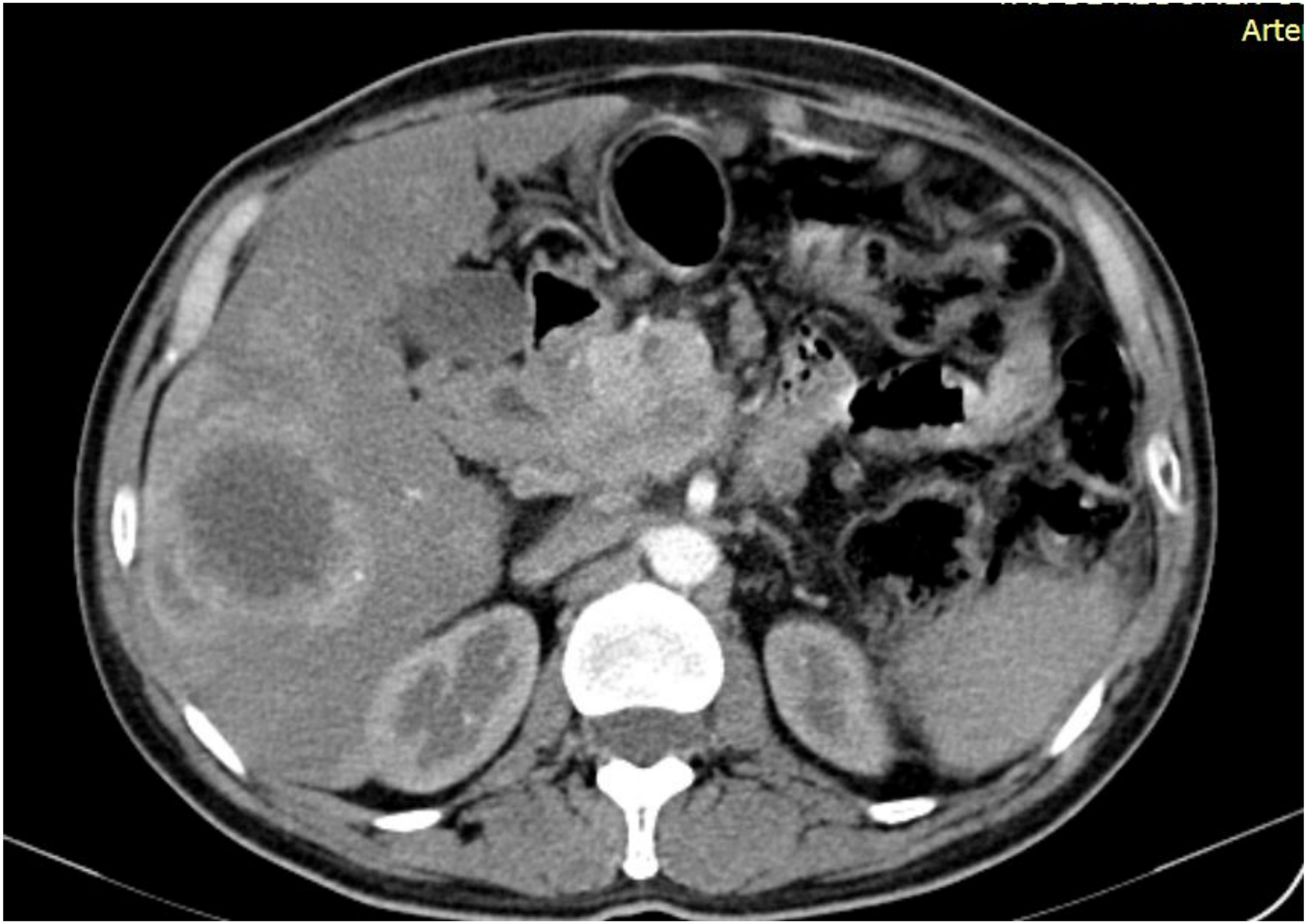
Arte

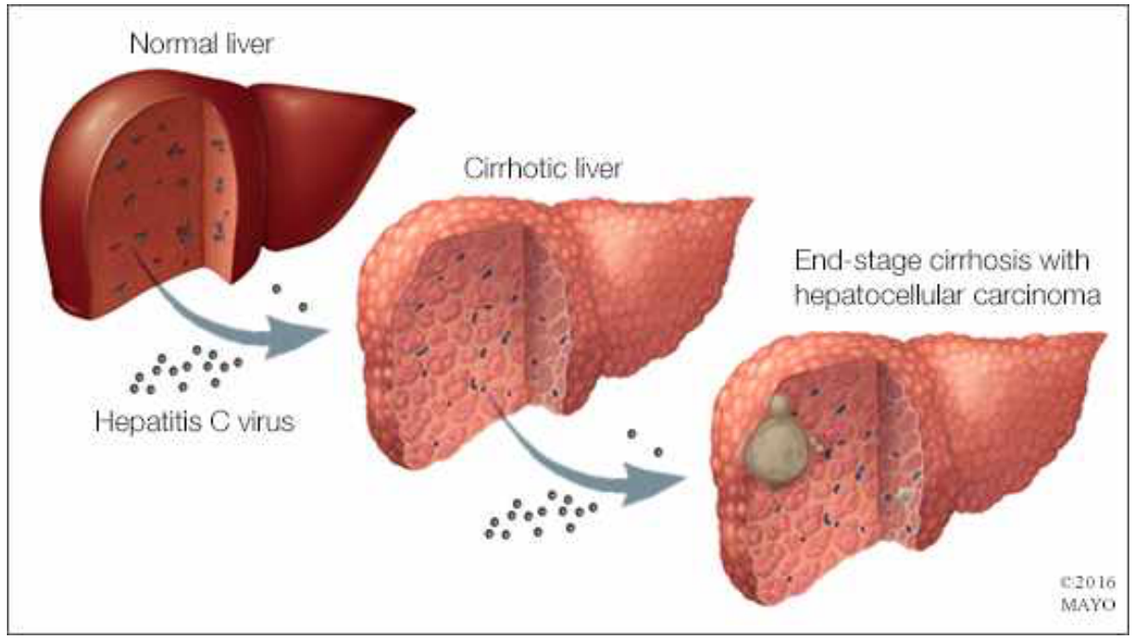
Normal liver
Cirrhotic liver
End-stage cirrhosis with
hepatocellular carcinoma
Hepatitis C virus
©2016
MAYO

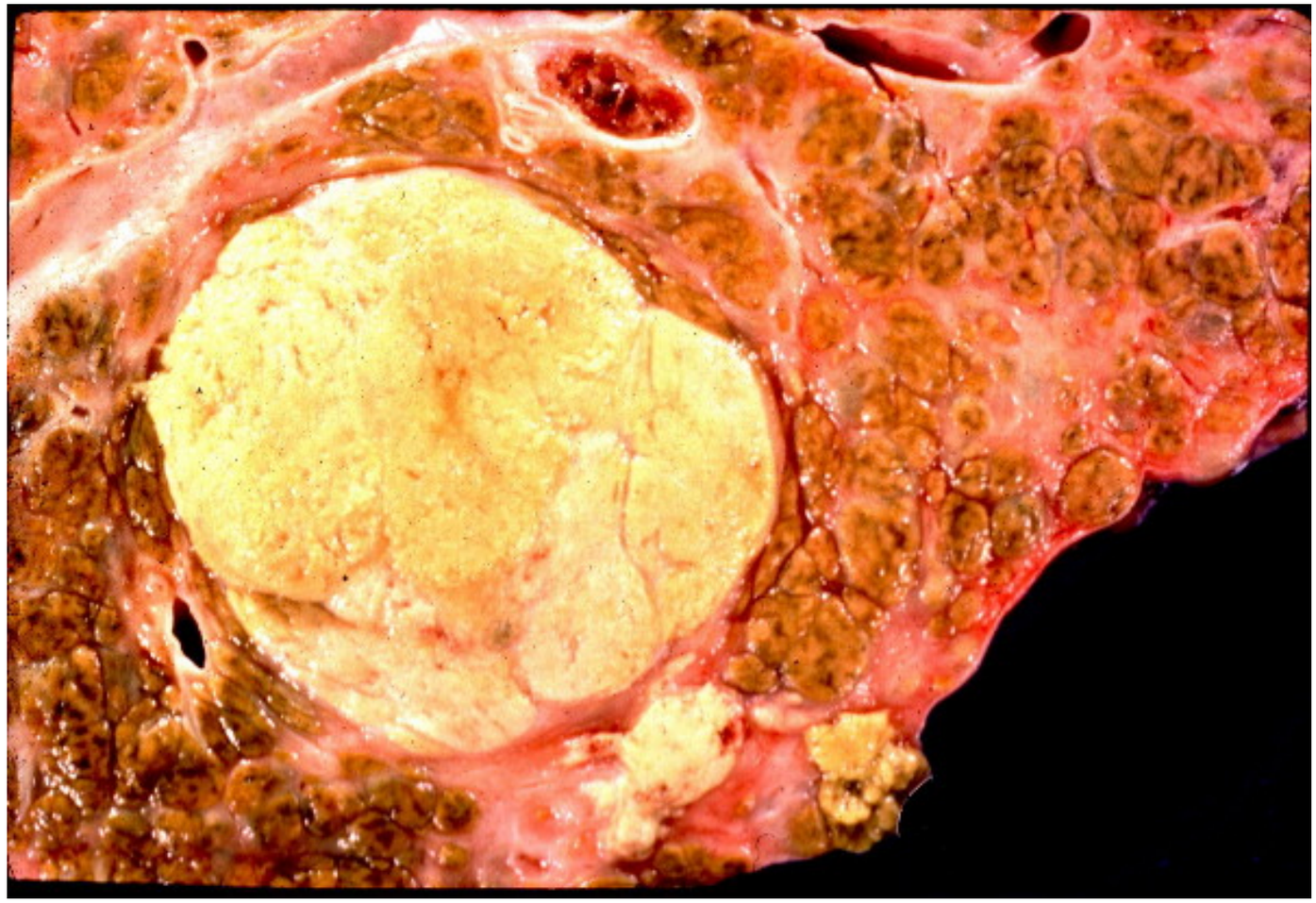

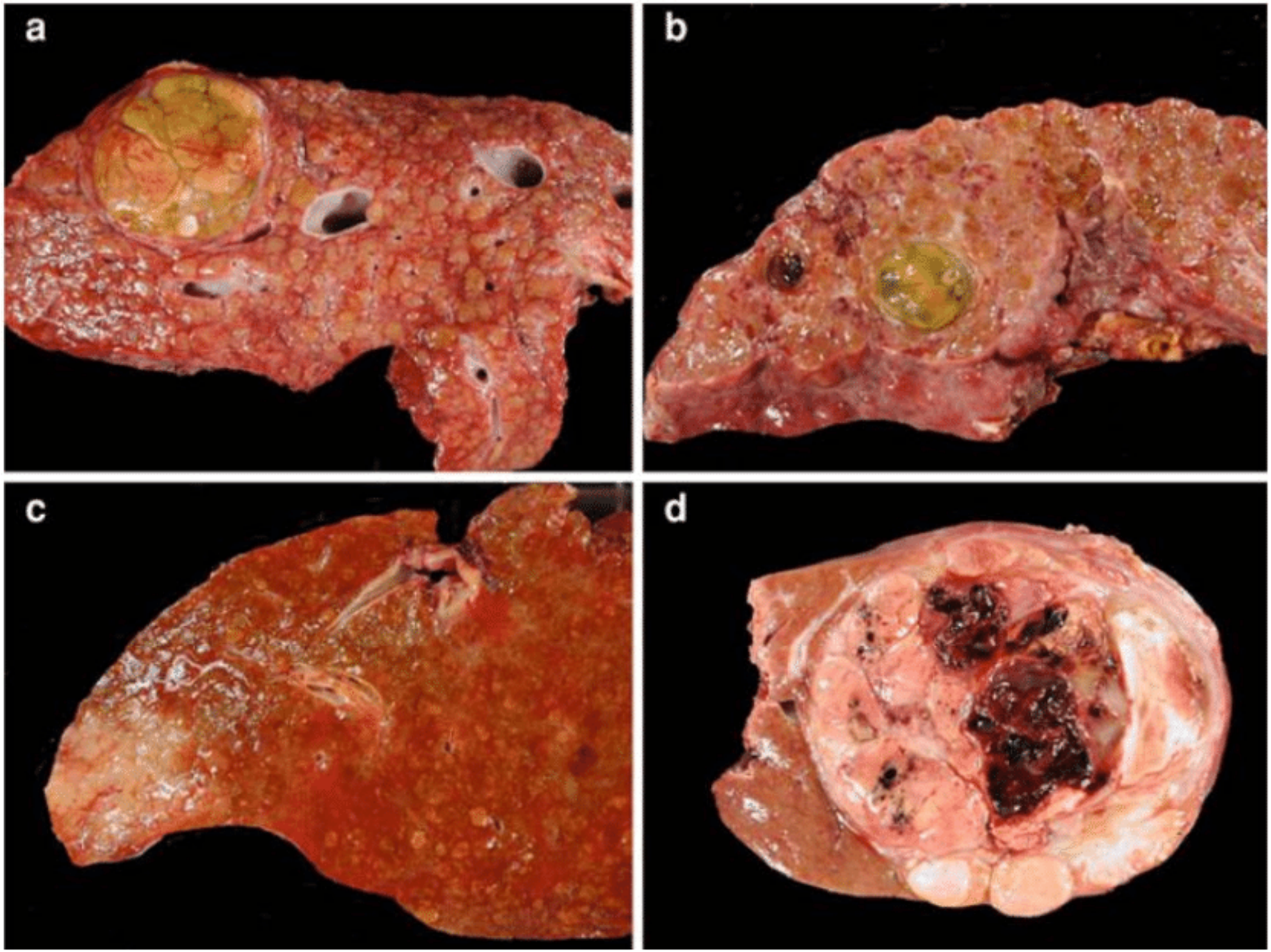
a
b
c
d

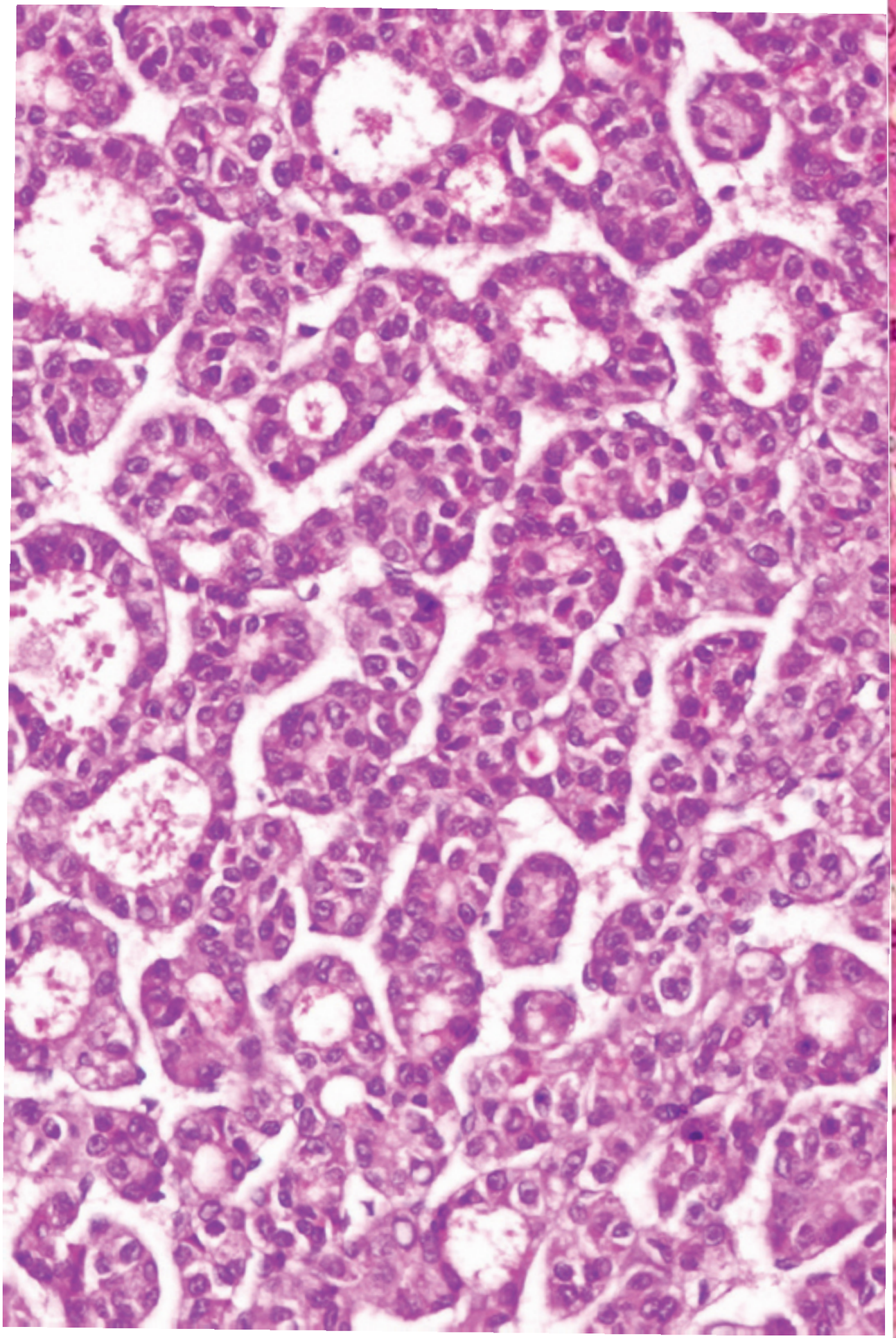

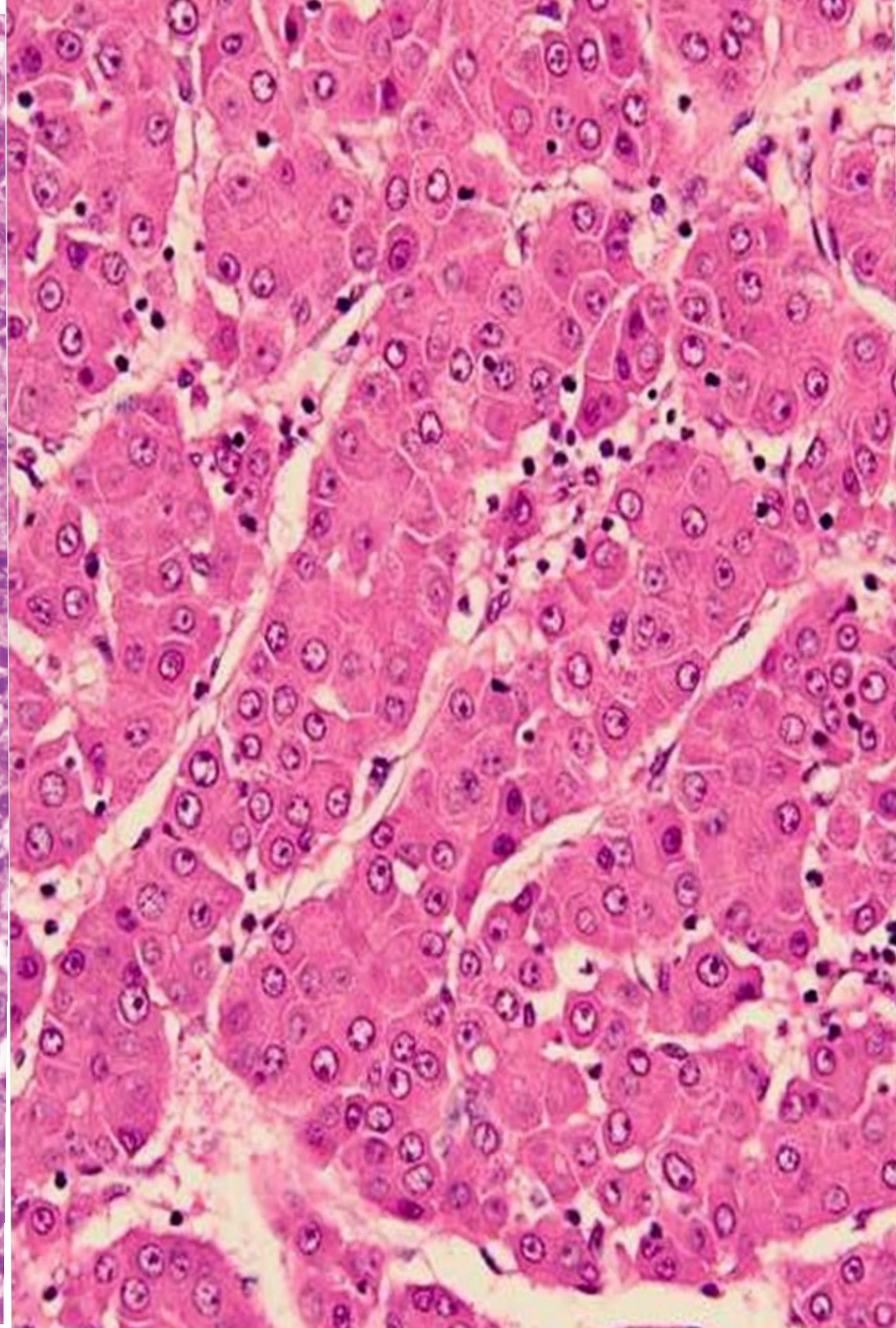

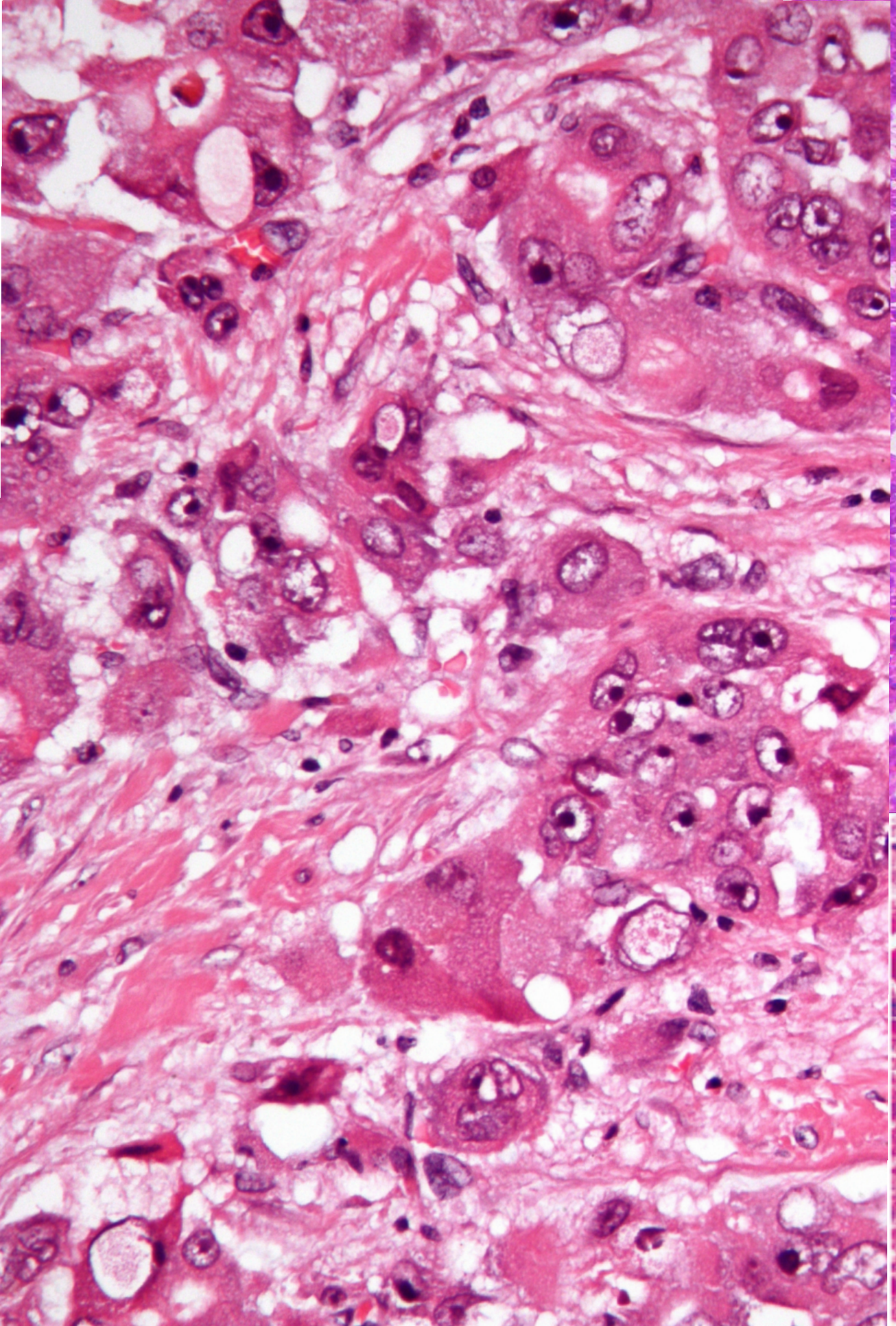

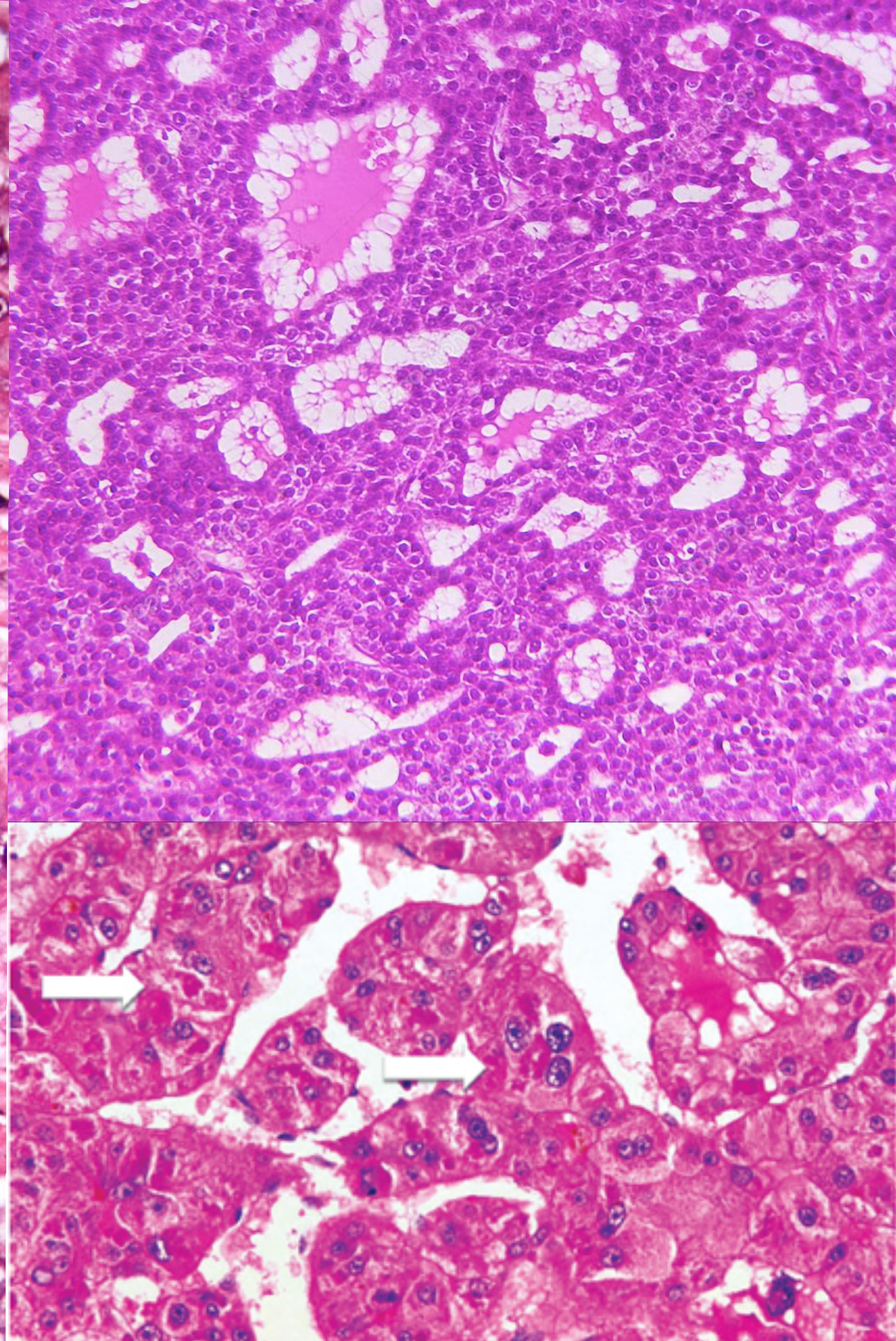

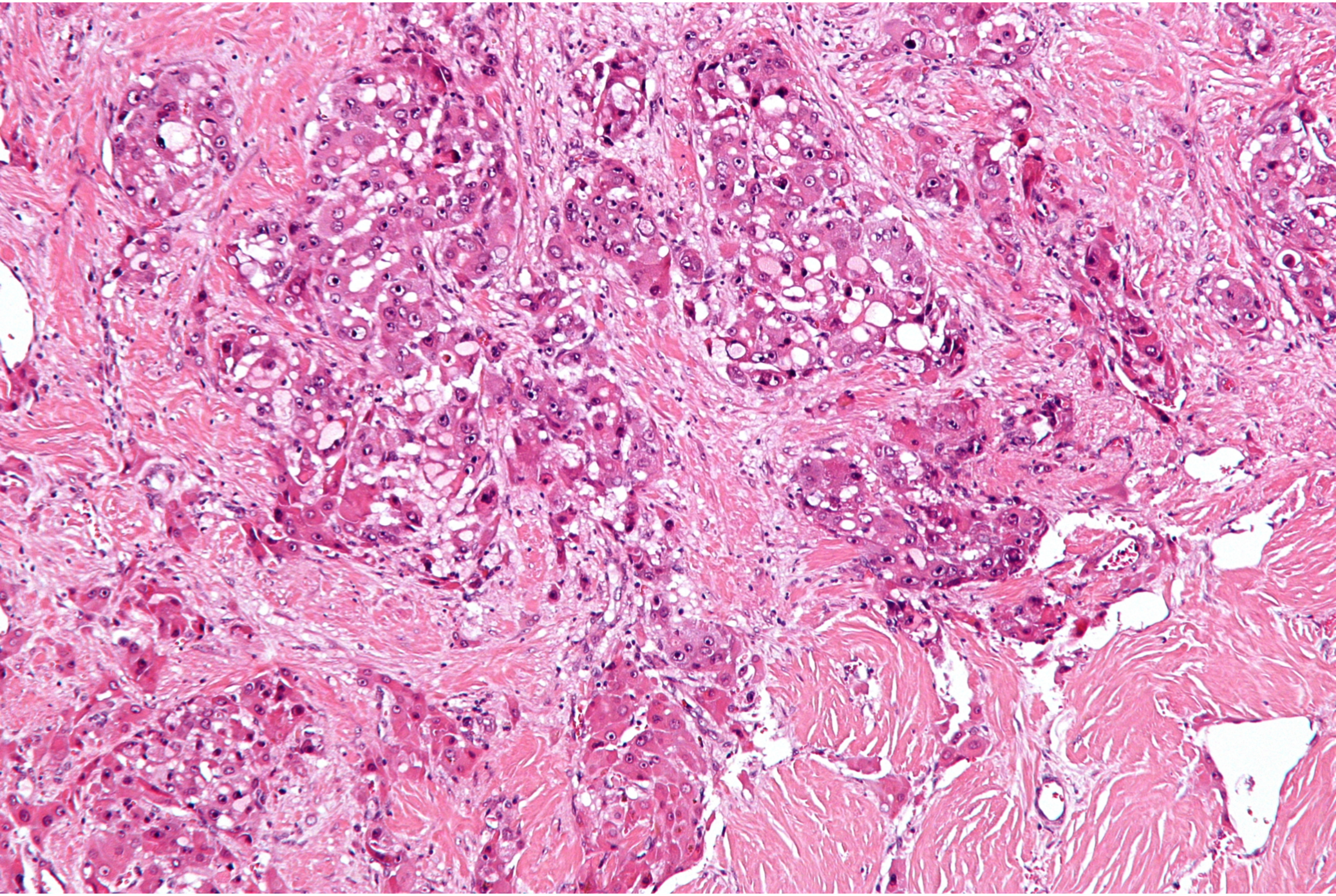

SARCOMAS

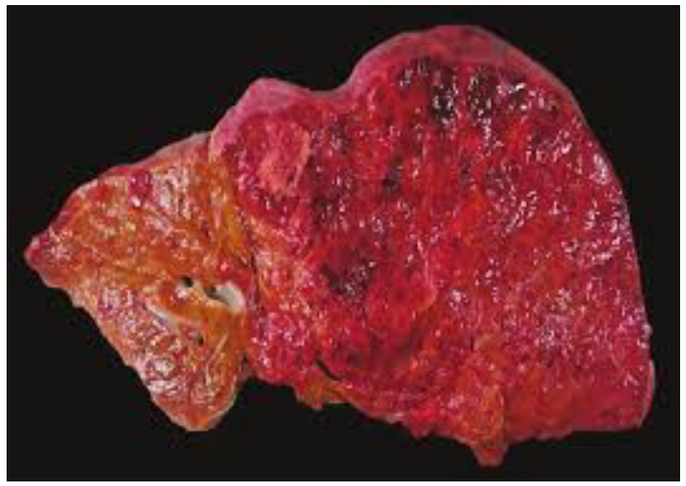

- **<u>ANGIOSARCOMA</u>**
  - Thorotrast(1950), cloruro de vinilo, arsénico y esteroides anabólicos
  - H:M 3:1, >60 años
  - Multicentrico, hemorrágico, quistico
  - CD34, CD31, VIMENTINA

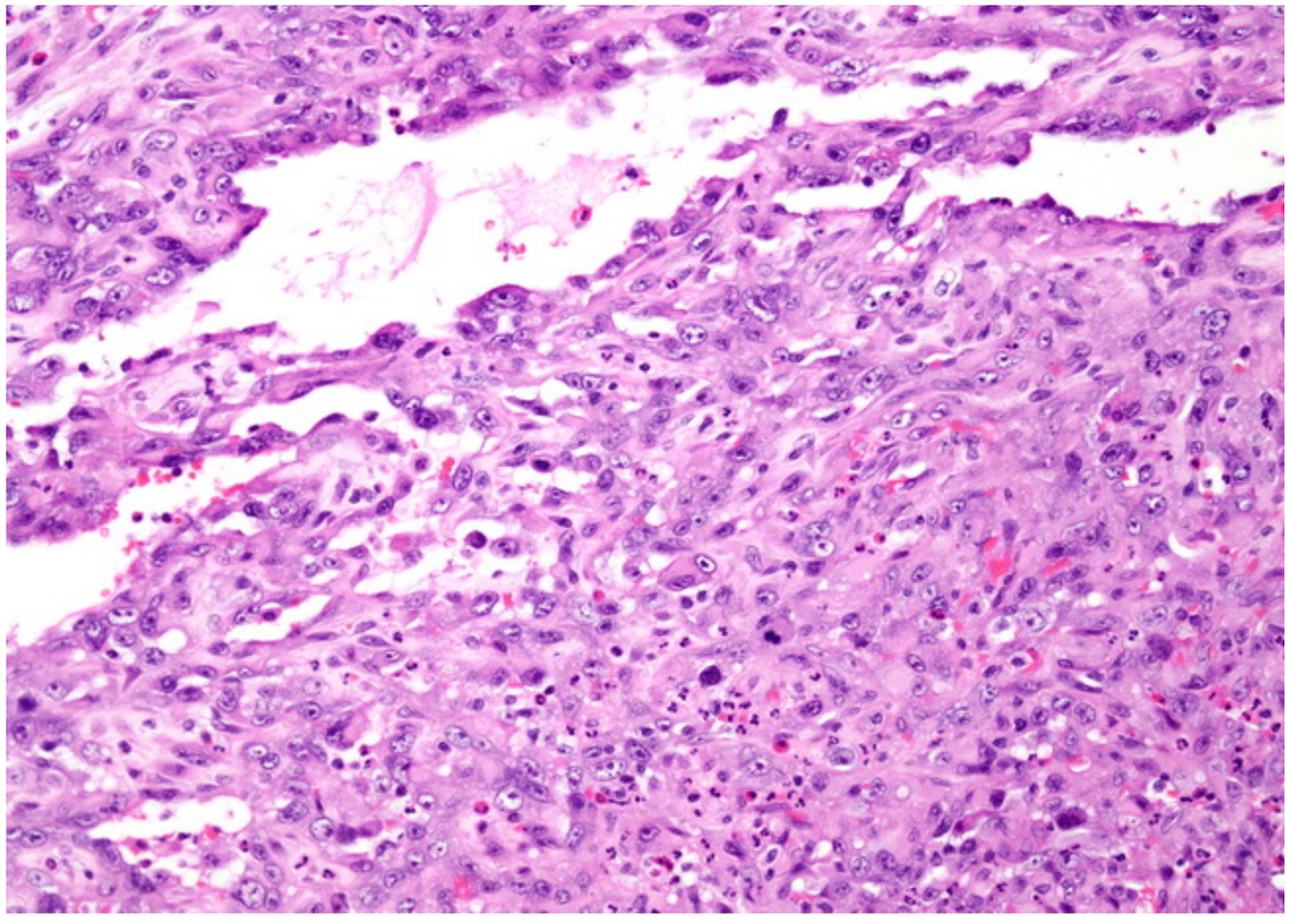

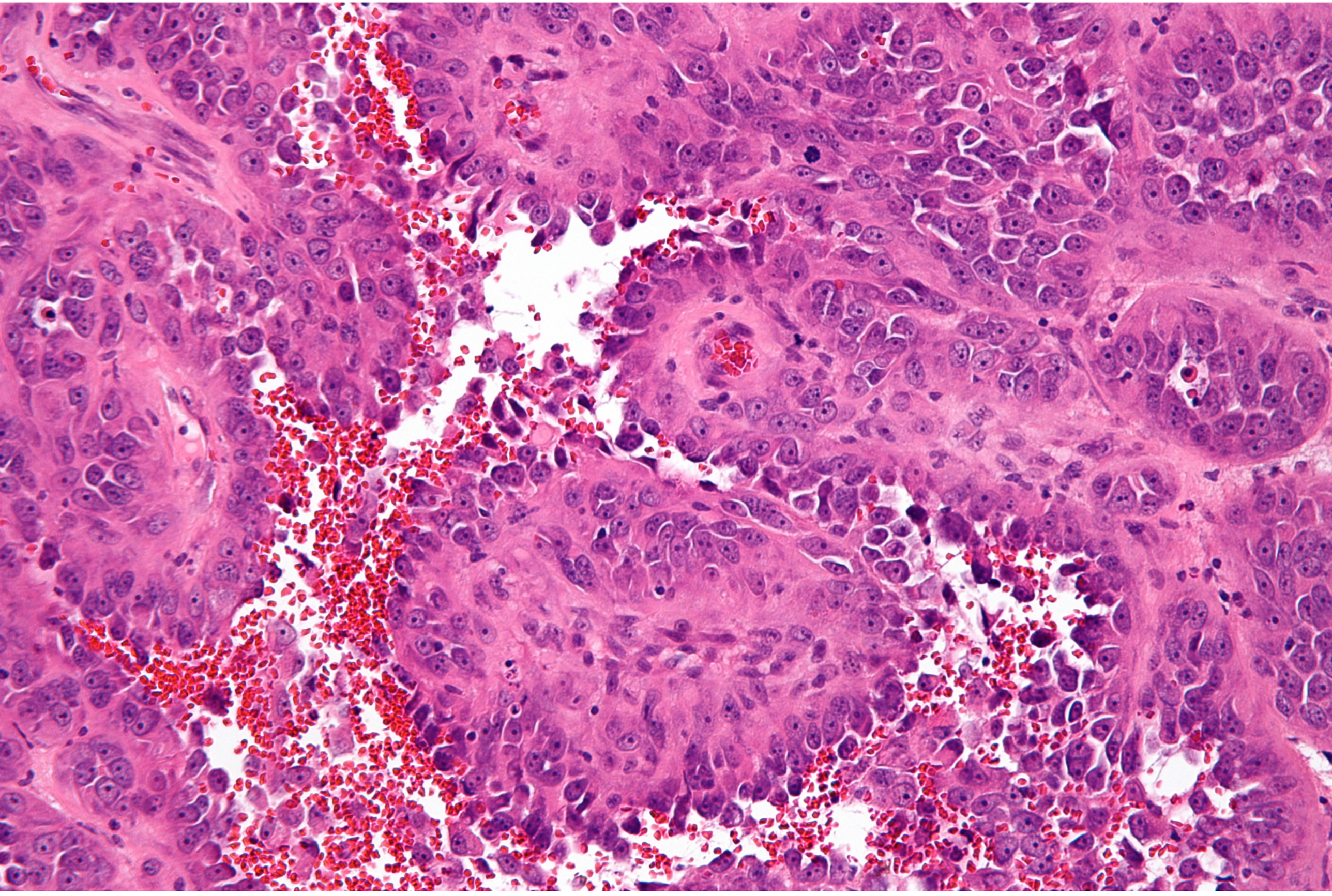

SARCOMAS

- **<u>SARCOMA EMBRIONARIO</u>**
  - EDAD PEDIÁTRICA
  - 6-10 AÑOS
  - MASA GRANDE DE RAPIDO CRECIMIENTO, PALPABLE
  - MUERTE SEMANAS A MESE
  - BIEN LIMITADO, EXTENSA NECROSIS, HEMORRAGIA Y DEGENERACIÓN QUÍSTICA
  - FUSOCELULAR ANAPLÁSICO
  - PAS POSITIVOS GLOBULOS Y aFETOPROTEINA

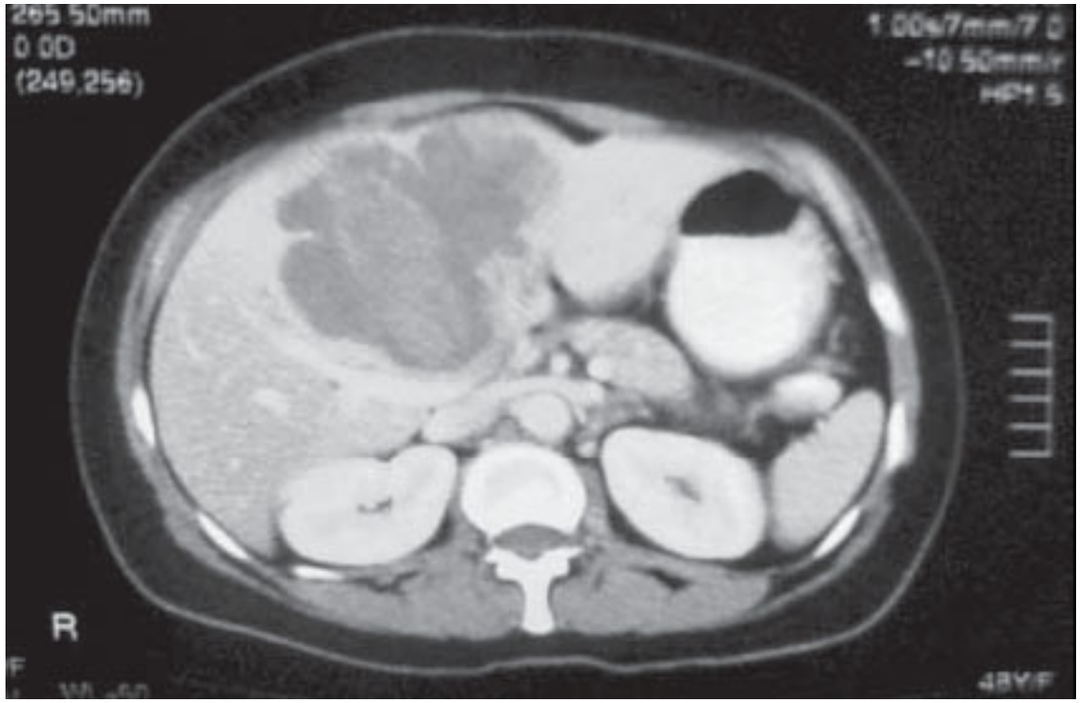

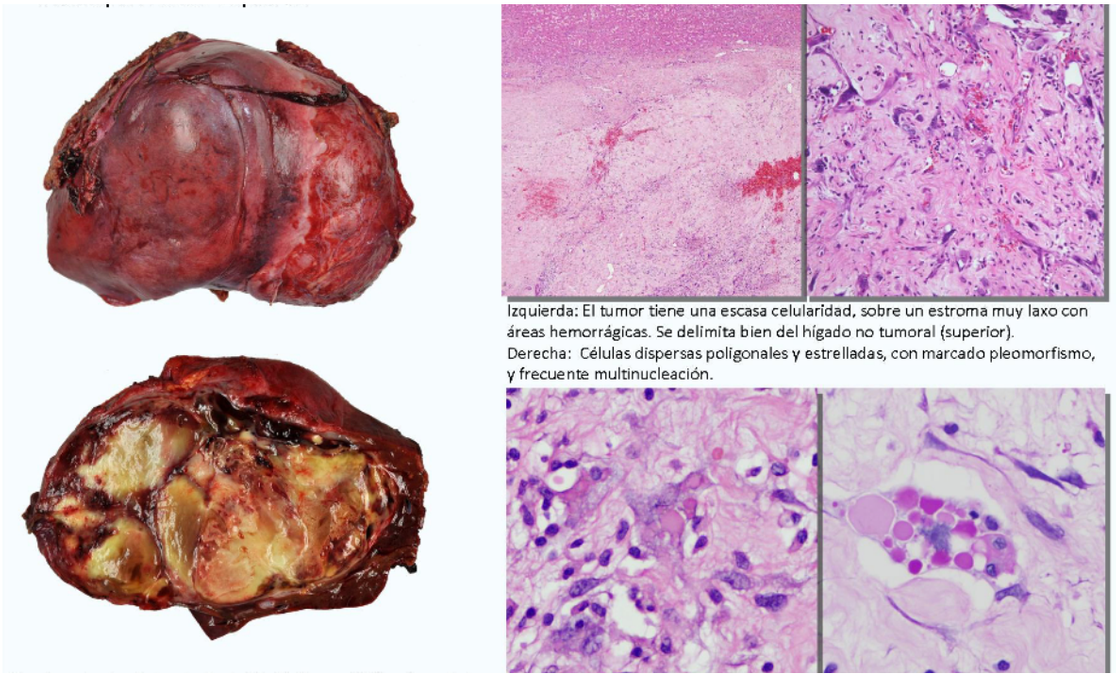
Izquierda: El tumor tiene una escasa celularidad, sobre un estroma muy laxo con áreas hemorrágicas. Se delimita bien del hígado no tumoral (superior).
Derecha: Células dispersas poligonales y estrelladas, con marcado pleomorfismo, y frecuente multinucleación.