TUMORES DEL SNC

DRA. MONICA CARRERA

TUMORES DE CEL NEUROGLIALES	CELULAS GLIALES	CEL EPENDIMARIAS	PLEXOS COROIDES	T. NEURONALES
TUMORES EMBRIONARIOS	MEDULOBLASTOMA	T. TERATOIDE		
TUMORES CRANEALES Y NERVIOS ESPINALES	SCHWANNOMA	NEUROFIBROMA	TMVNP	
TUMORES MENINGEOS	MENINGIOMA			
TUMORS MESENQUIMATOSO	HEMANGIOBLASTOMA	T. FIBROSO SOLITARIO	SARCOMA	
TUMORES DE CEL GERMINALES	GERMINOMA	DA EMBRIONARIO	SENOS ENDODERMICOS	TERATOMA
TUMORES METASTÁSICOS	PULMON	MAMA	MELANOMA	RENAL
T. REGION SELLAR	CRANEOFARINGIOMA			
LINFOMAS	CÉLULAS GRANDES B INMUNOCOMPETENTES			

INTRA AXIAL

EXTRA AXIAL

ALTERACIONES GENETICAS RELACIONADAS A ALGUNOS TUMORES DE SN

SYNDROME	GENE/LOCUS	NS TUMORS	OTHER TUMORS
NF1	*NF1*/17q	Plexiform neurofibroma, MPNST, optic and other gliomas	Pheochromocytoma, GIST
NF2	*NF2*/22q	Vestibular and PN shwannoma, meningioma, other brain tumors	NA
TS	*TSC1*/9q, *TSC2*/16p	SEGA	Renal AMLs, lung LAM, cardiac rhabdomyoma
VHL	*VHL*/3p	Hemangioblastoma	Renal cell carcinoma, pheochromocytoma
Li-Fraumeni	*TP53*/17p	Astrocytoma	Breast carcinoma, bone and soft tissue sarcoma
Turcot	*FAP*/5q	Medulloblastoma, GBM	GI polyps, colorectal cancer
Gorlin	*PTCH*/9q	Desmoplastic medulloblastoma	Nevoid basal cell carcinoma, Odontogenic keratocysts

WHO GRADING SYSTEM

Grade I-Pilocytic astrocytoma	Benign cytological features-see below
Grade II-Diffuse astrocytoma	Moderate cellularity-no anaplasia or mitotic activity
Grade III- Anaplastic astrocytoma	Cellularity, anaplasia, mitoses
Grade IV-Glioblastoma	Same as Grade III plus microvascular proliferation and necrosis

ASTROCITO EN MICROSCOPÍA ELECTRONICA

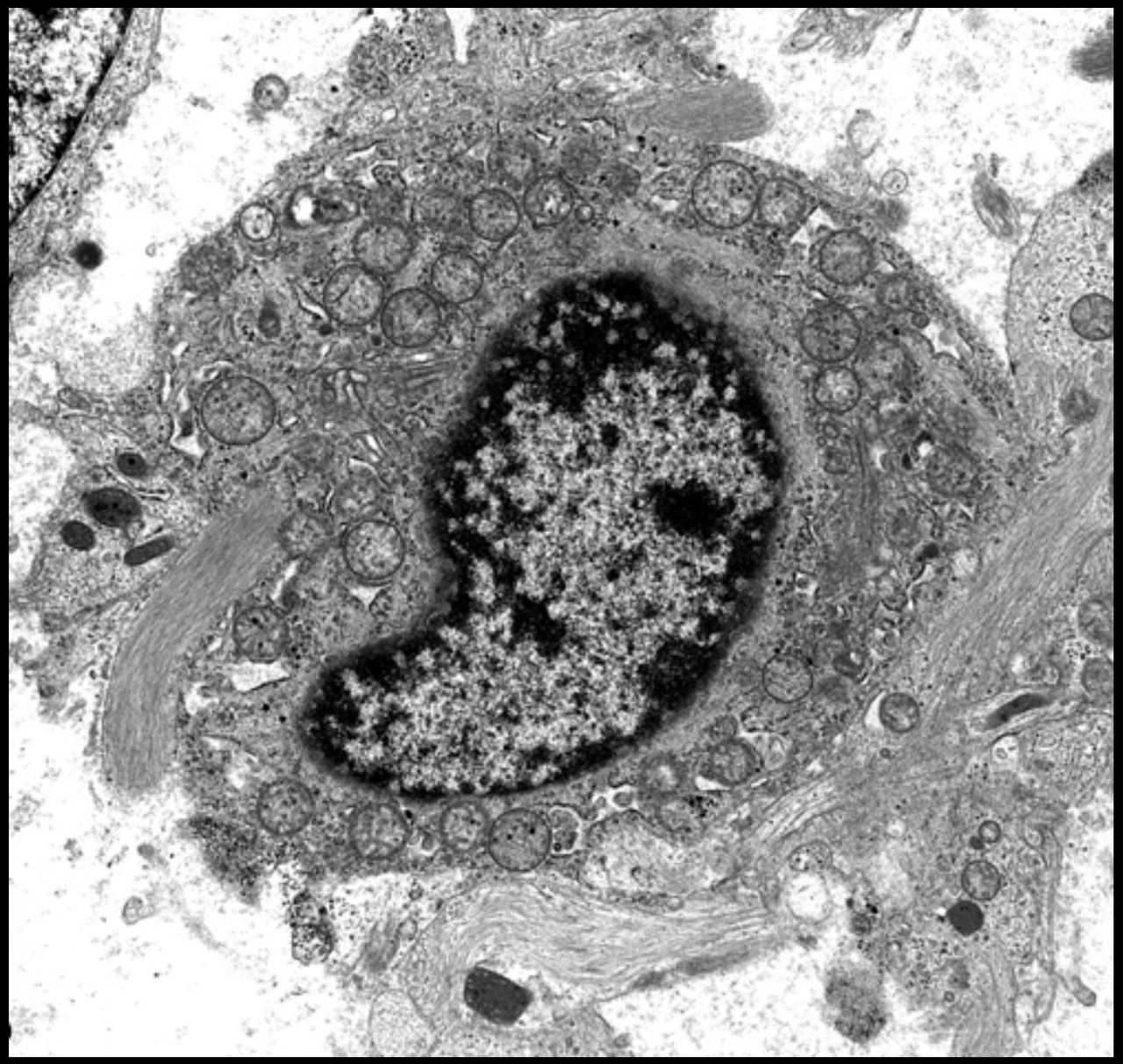

INMUNOHISTOQUIMICA PARA PROTEINA FIBRILAR ACIDA (GFCP)

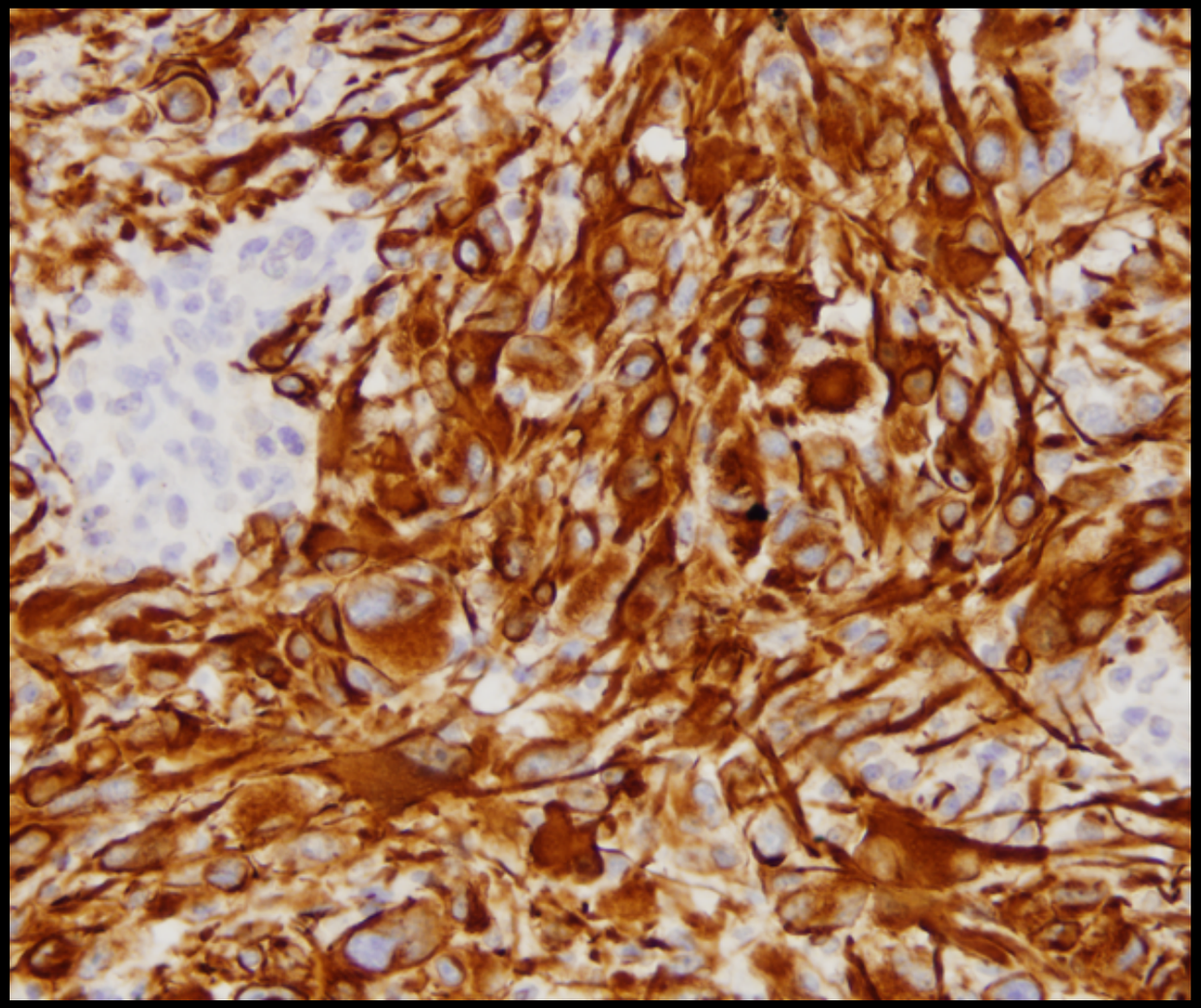

ASTROCITOMA DIFUSO

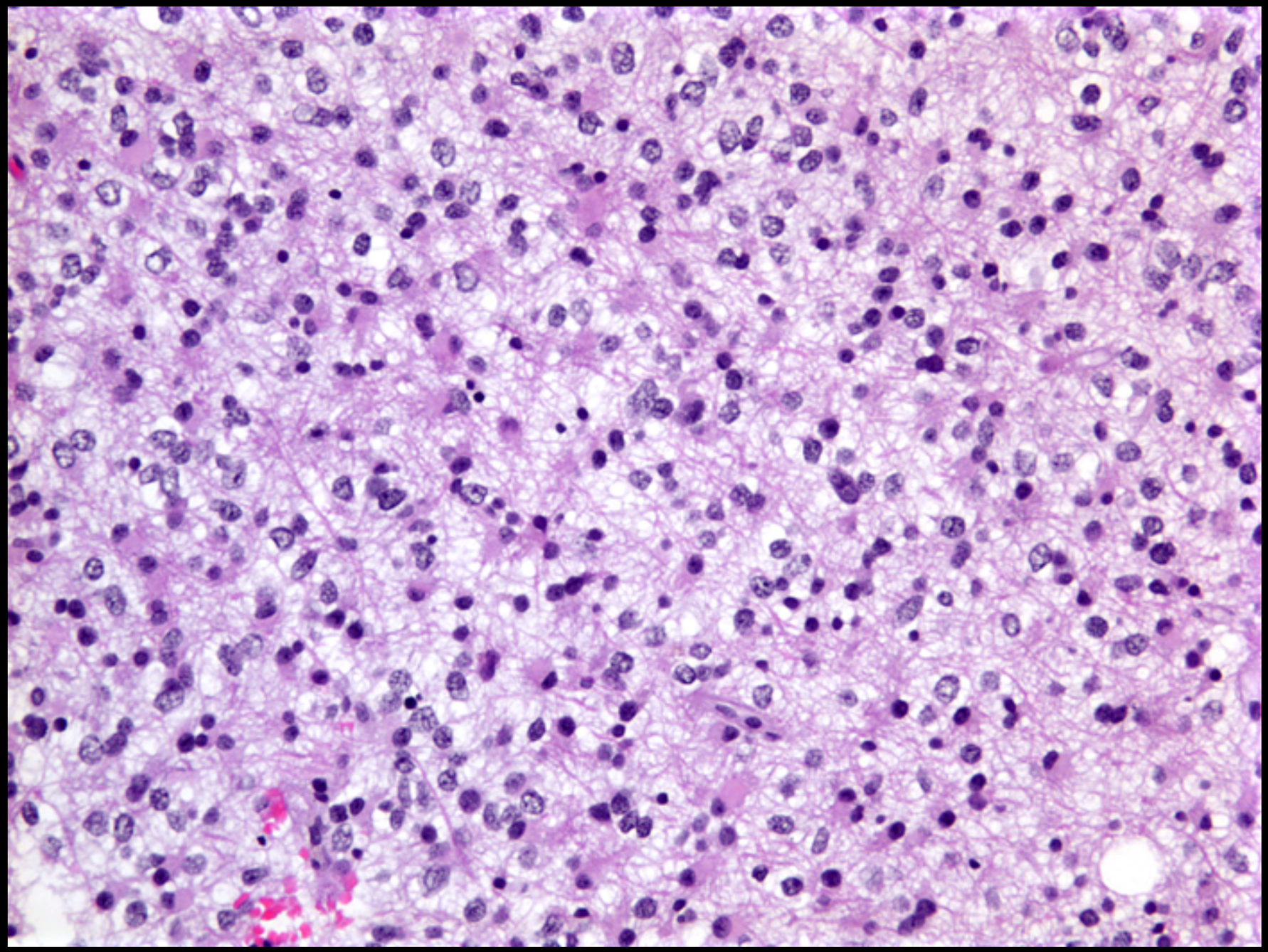

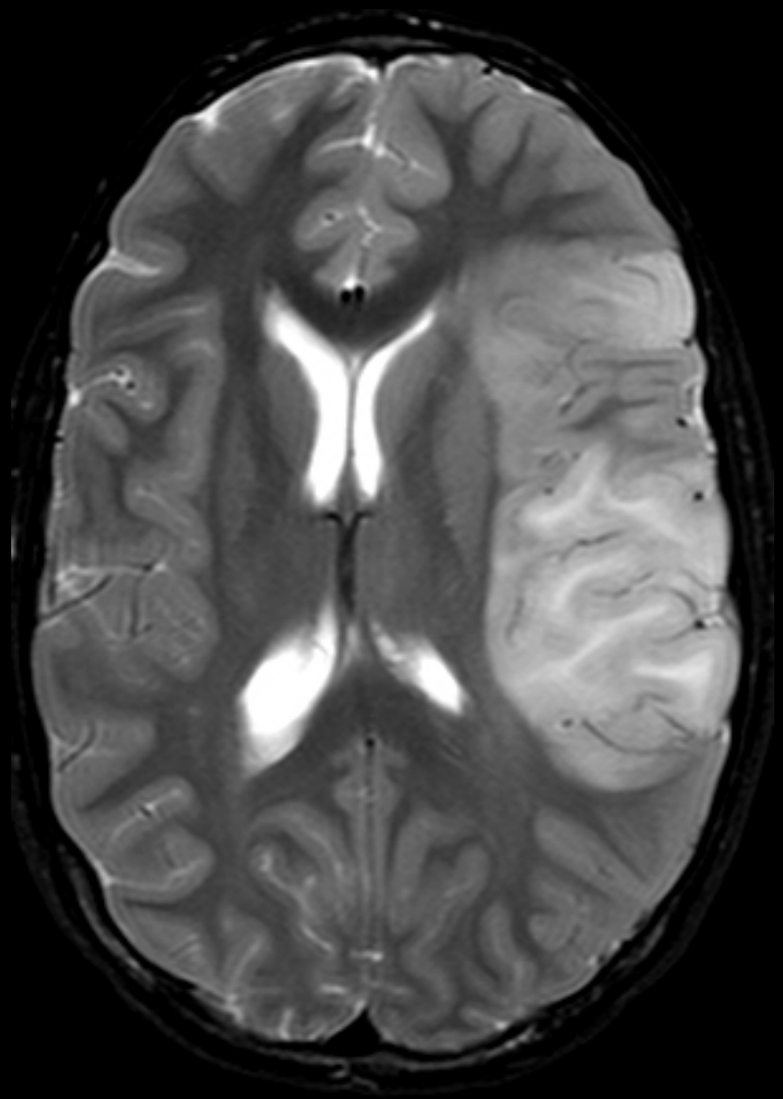

GLIOMATOSIS

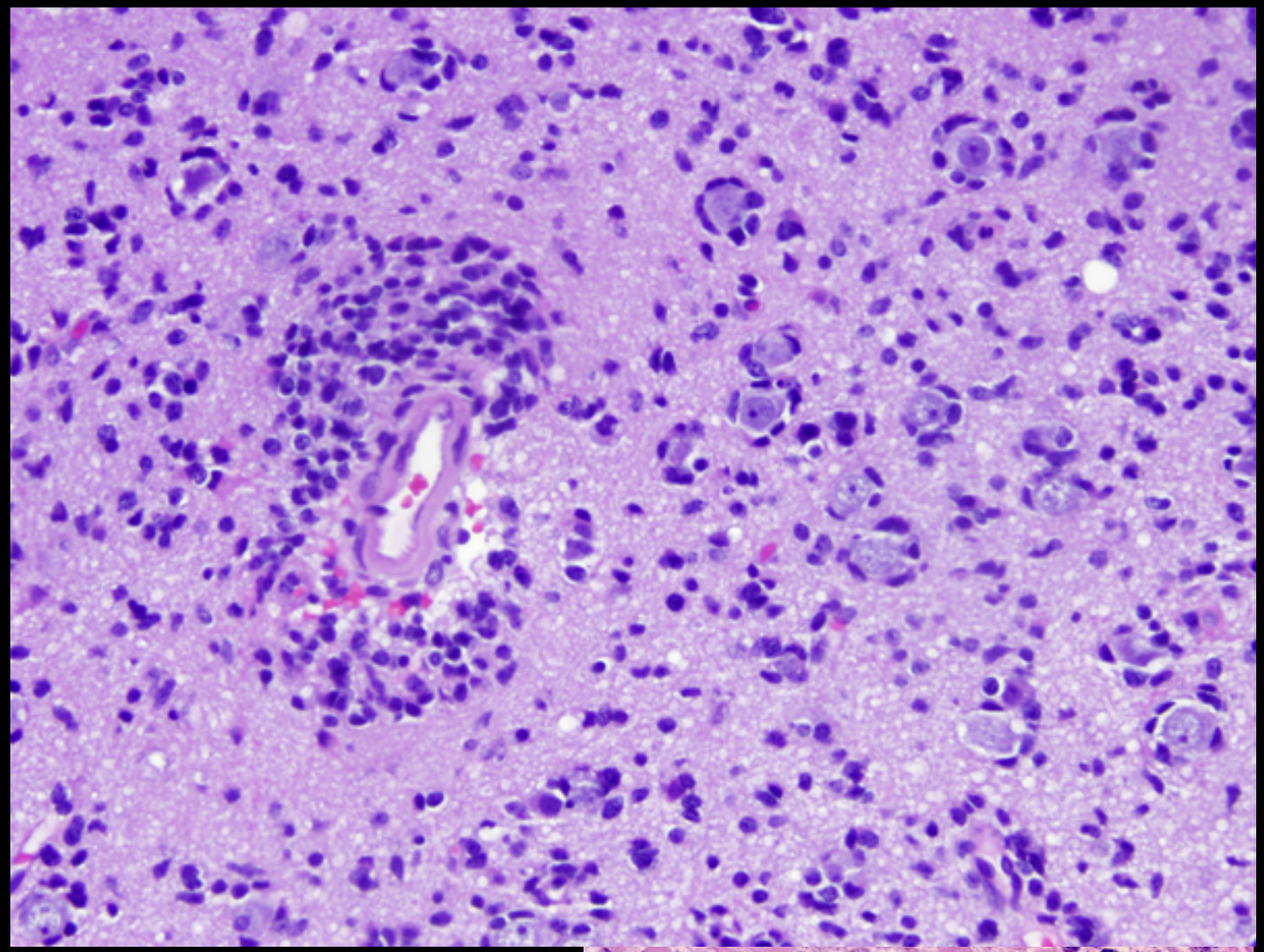

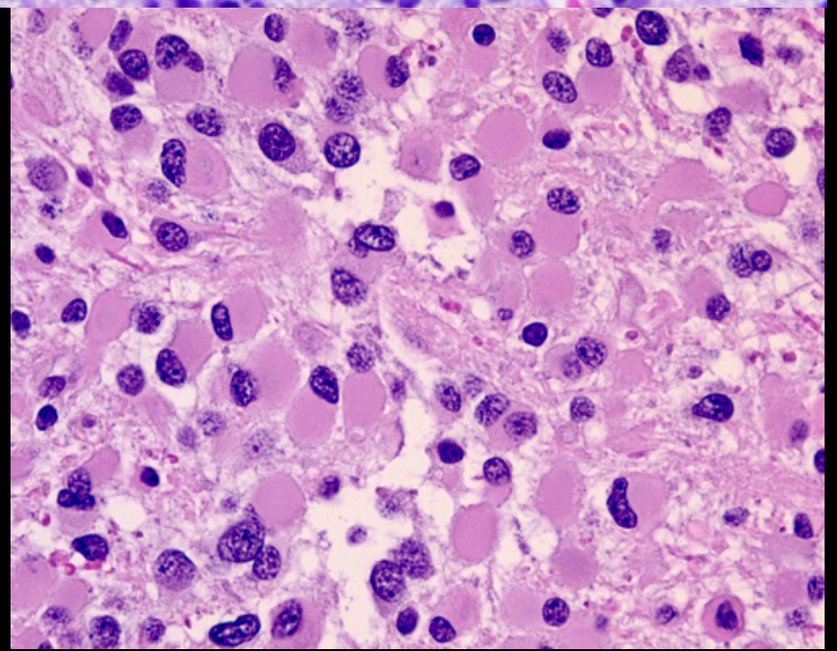

ASTROCITOMA GEMISTOCITICO

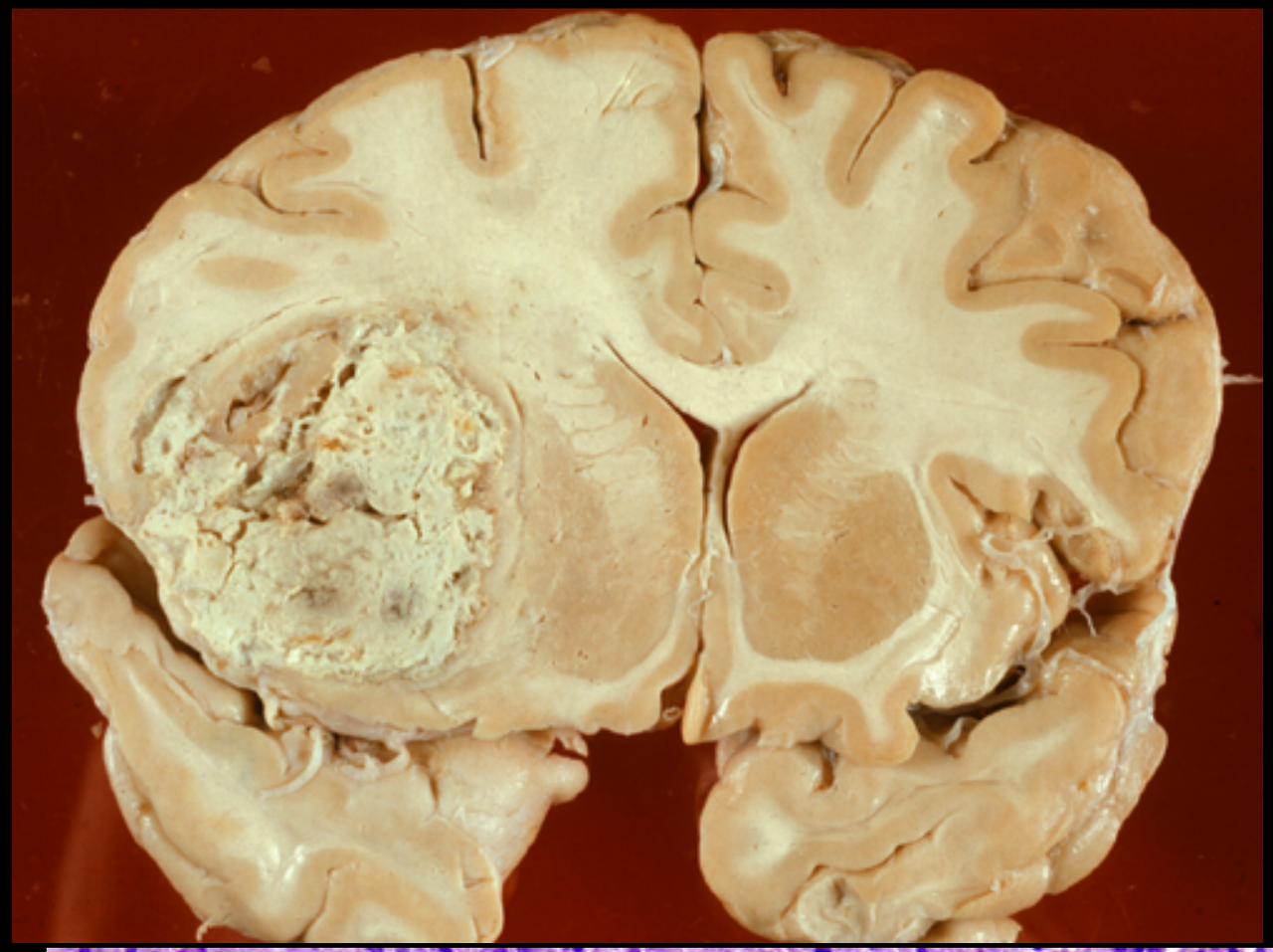

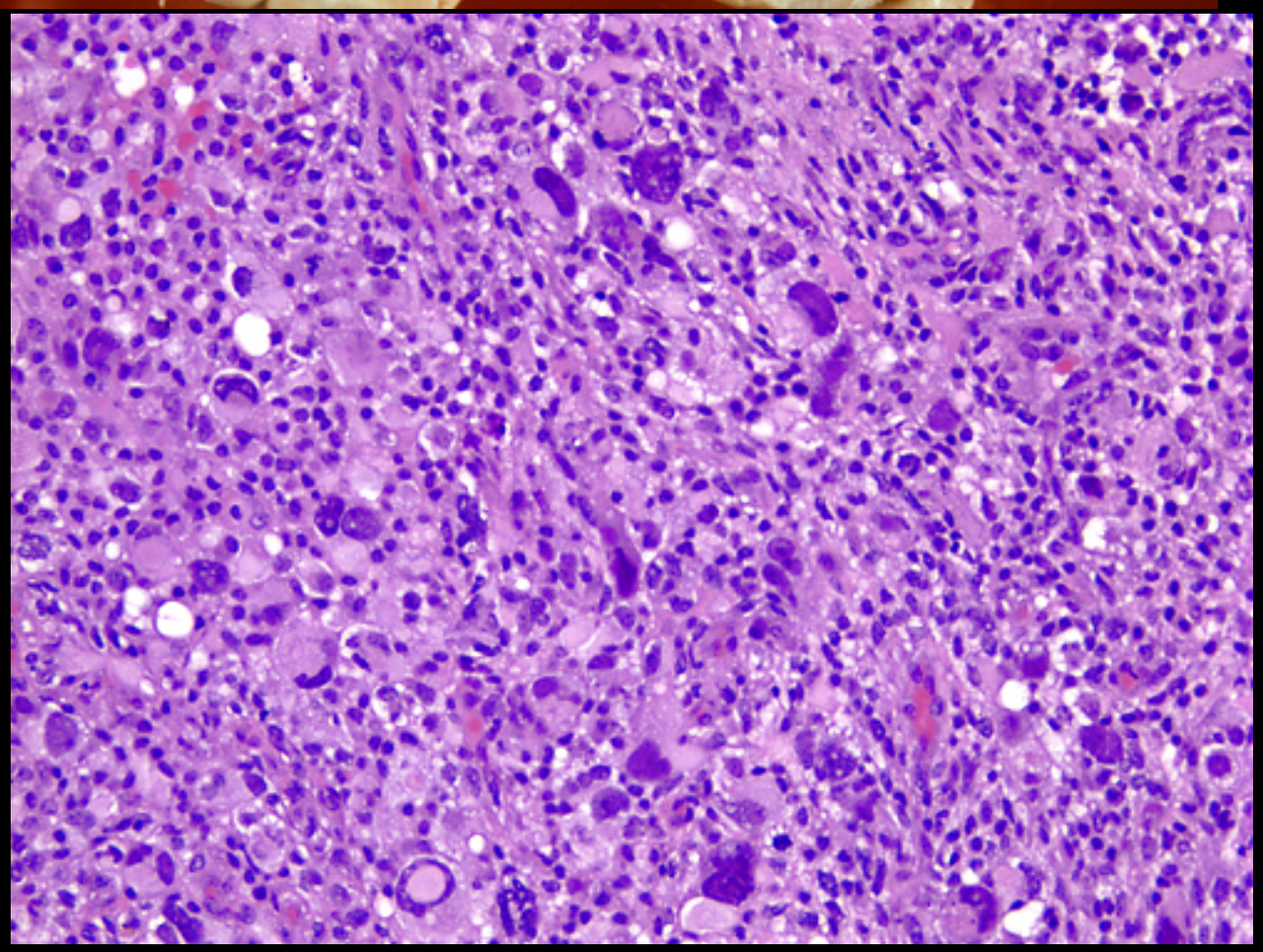

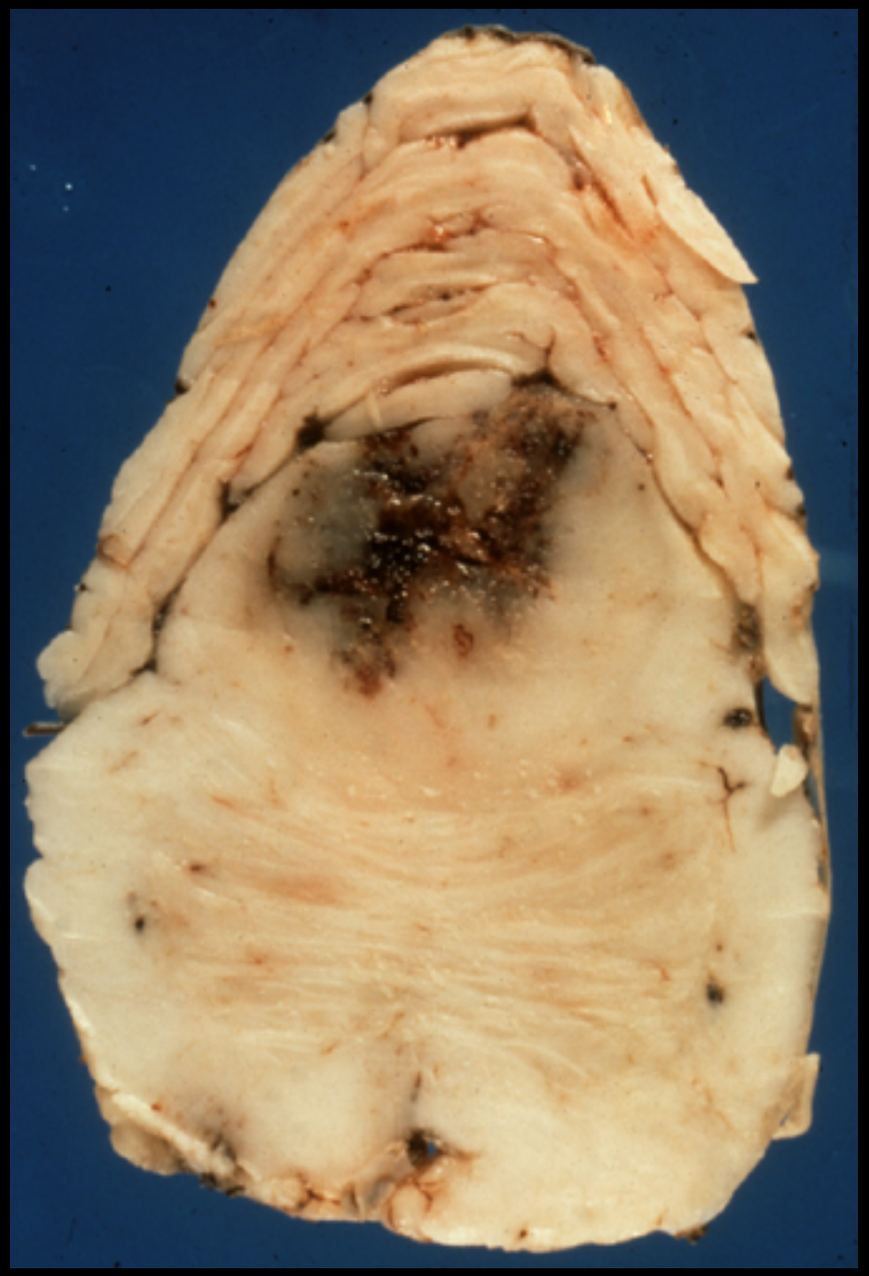

GBM DEL PUENTE

GLIOBLASTOMA MULTIFORME

GLIOBLASTOMA DE CÉLULAS GIGANTES

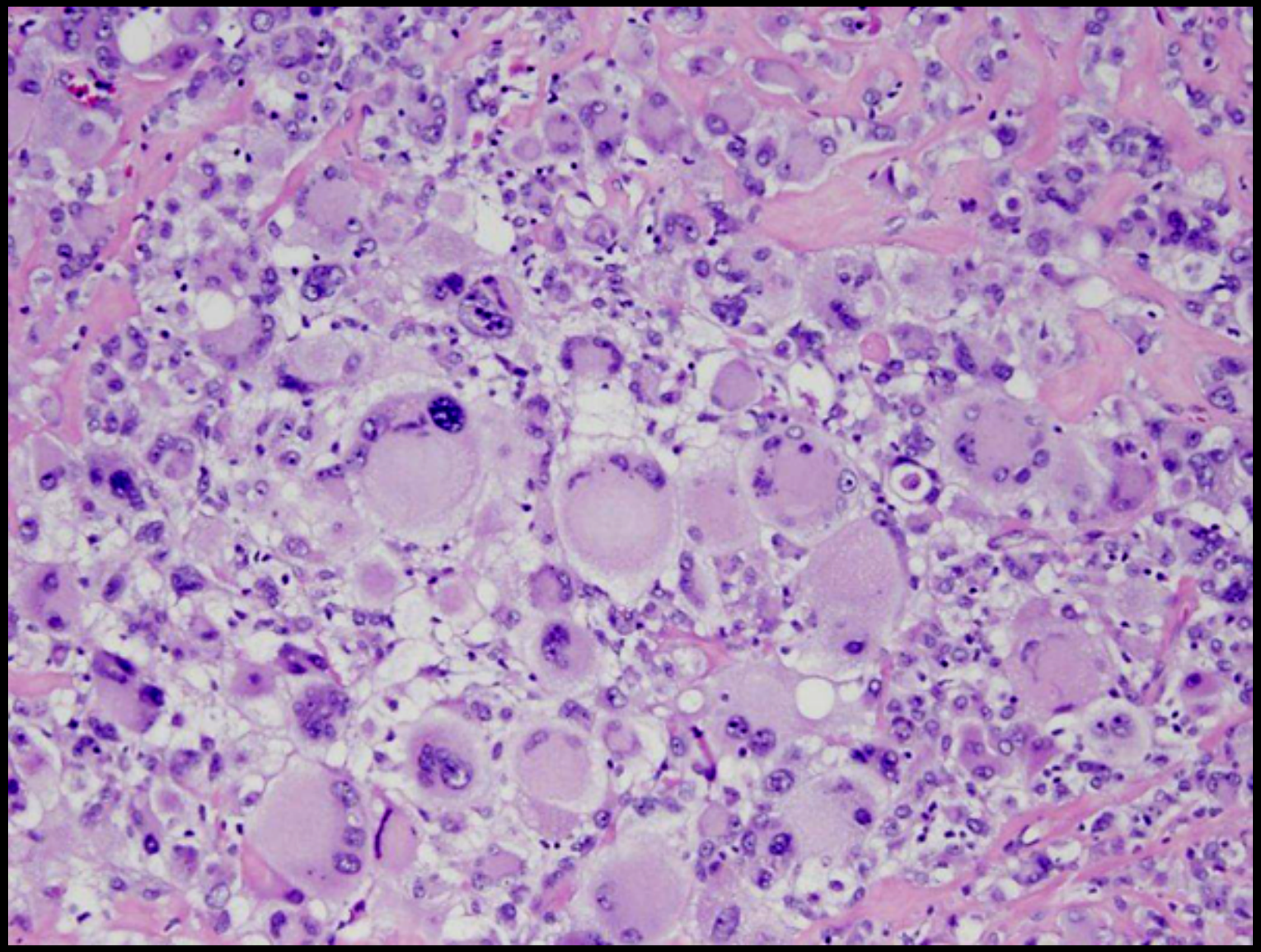

GLIOBLASTOMA DE CÉLULAS PEQUEÑAS

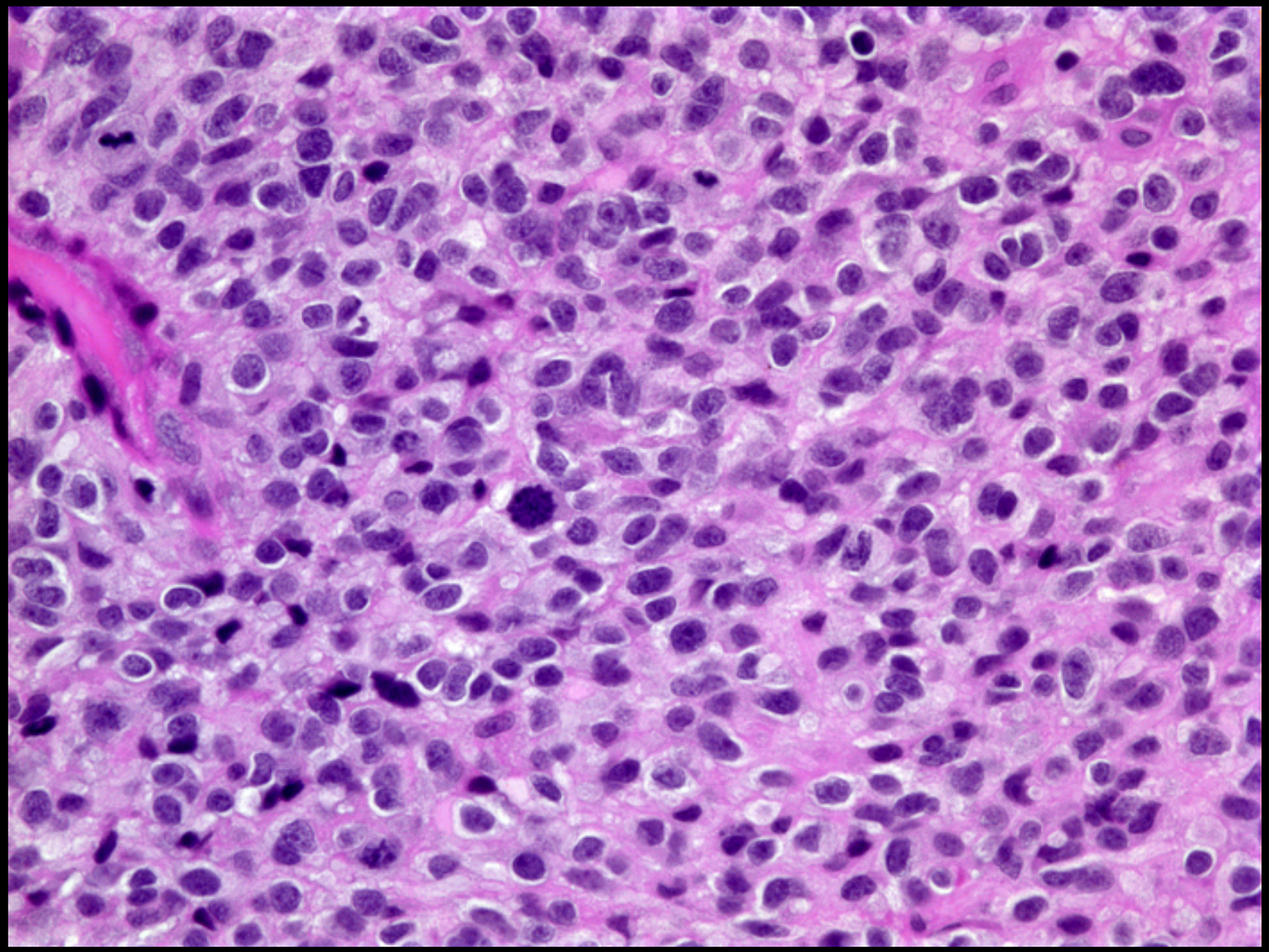

GBM: ZONAS DE NECROSIS EN PSEUDOEMPALIZADA

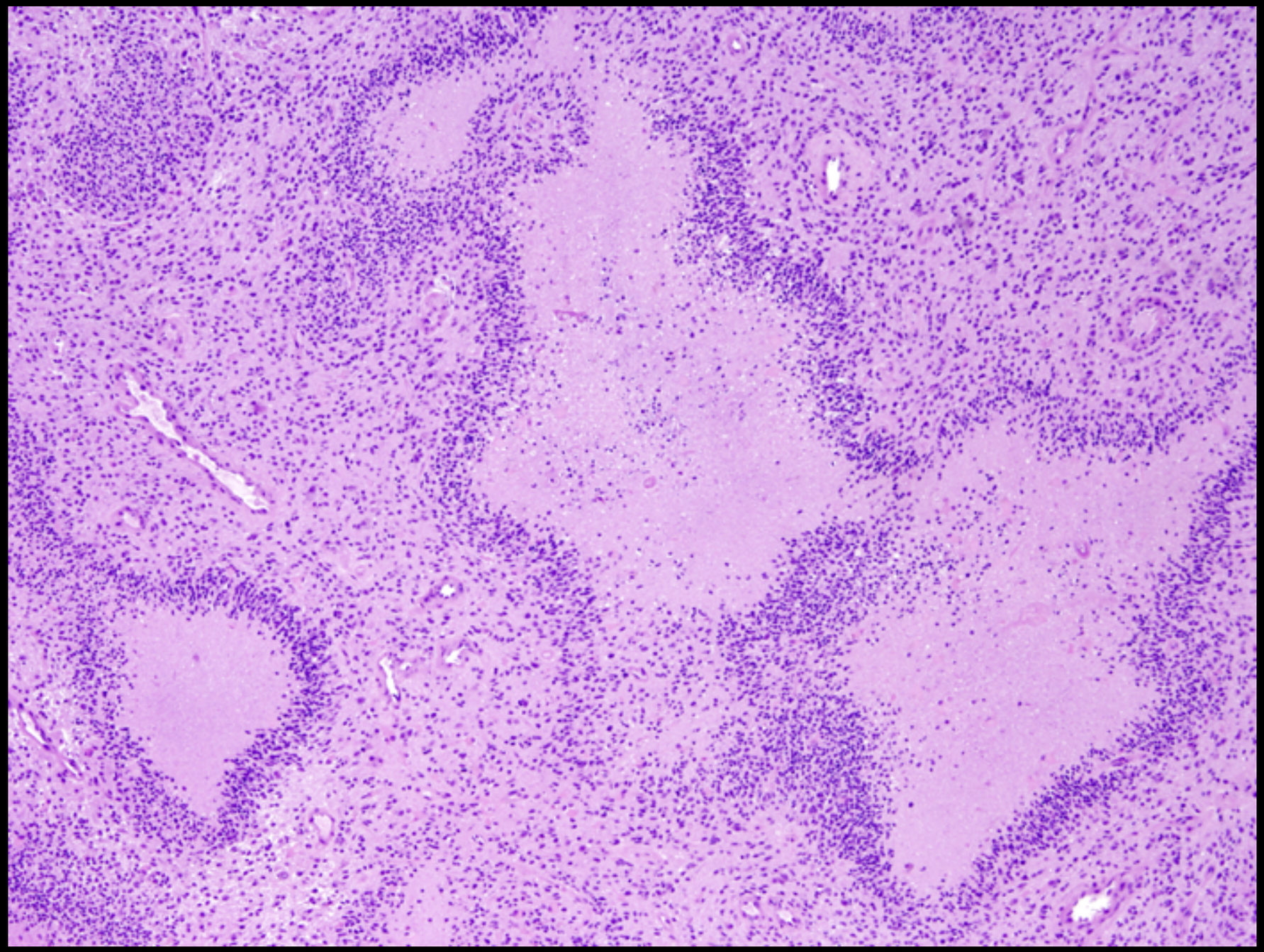

GBM CON PROLIFERACIÓN DE MICROVASCULATURA (VASOS GLOMERULOIDES)

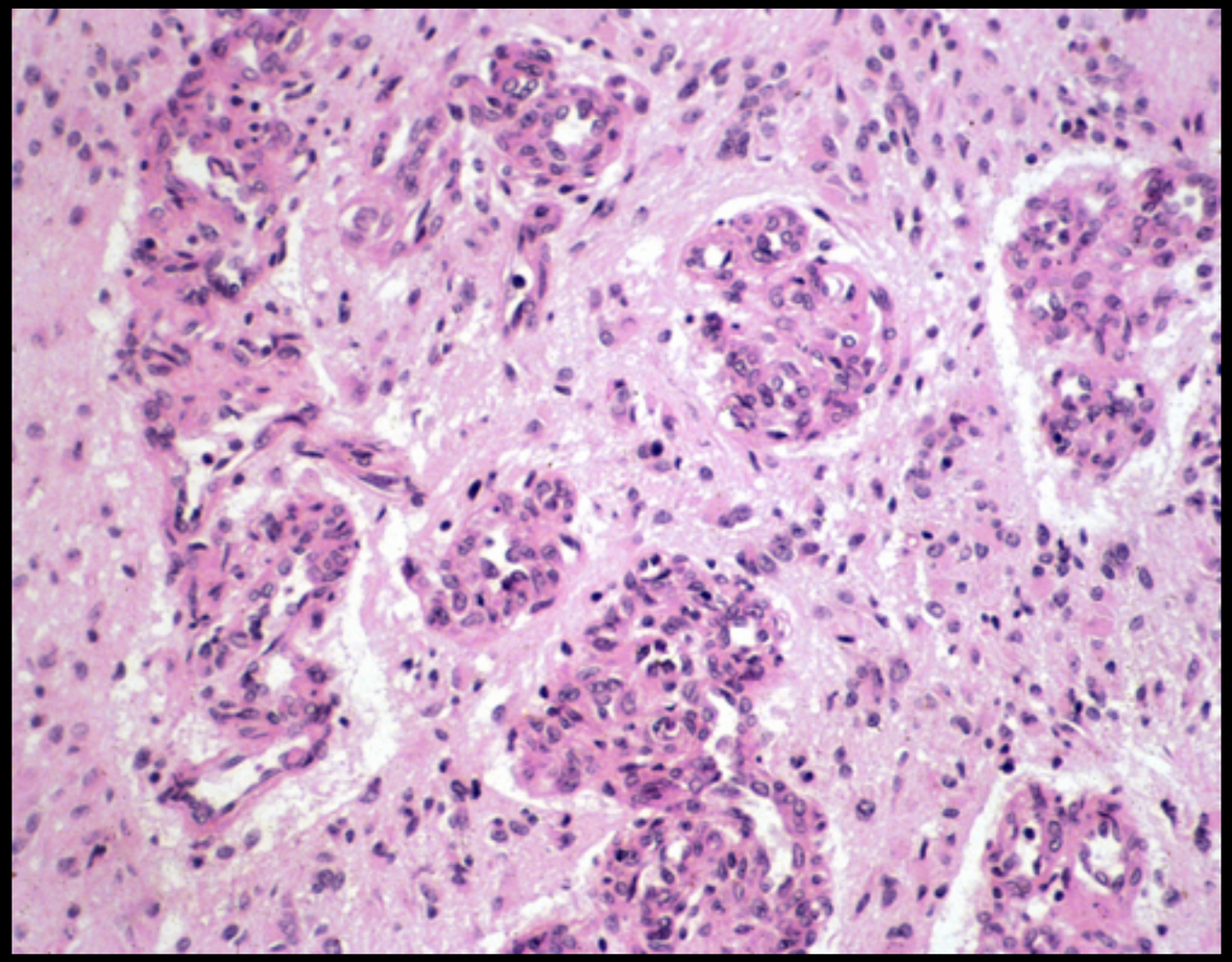

OLIGODENDROGLIOMA

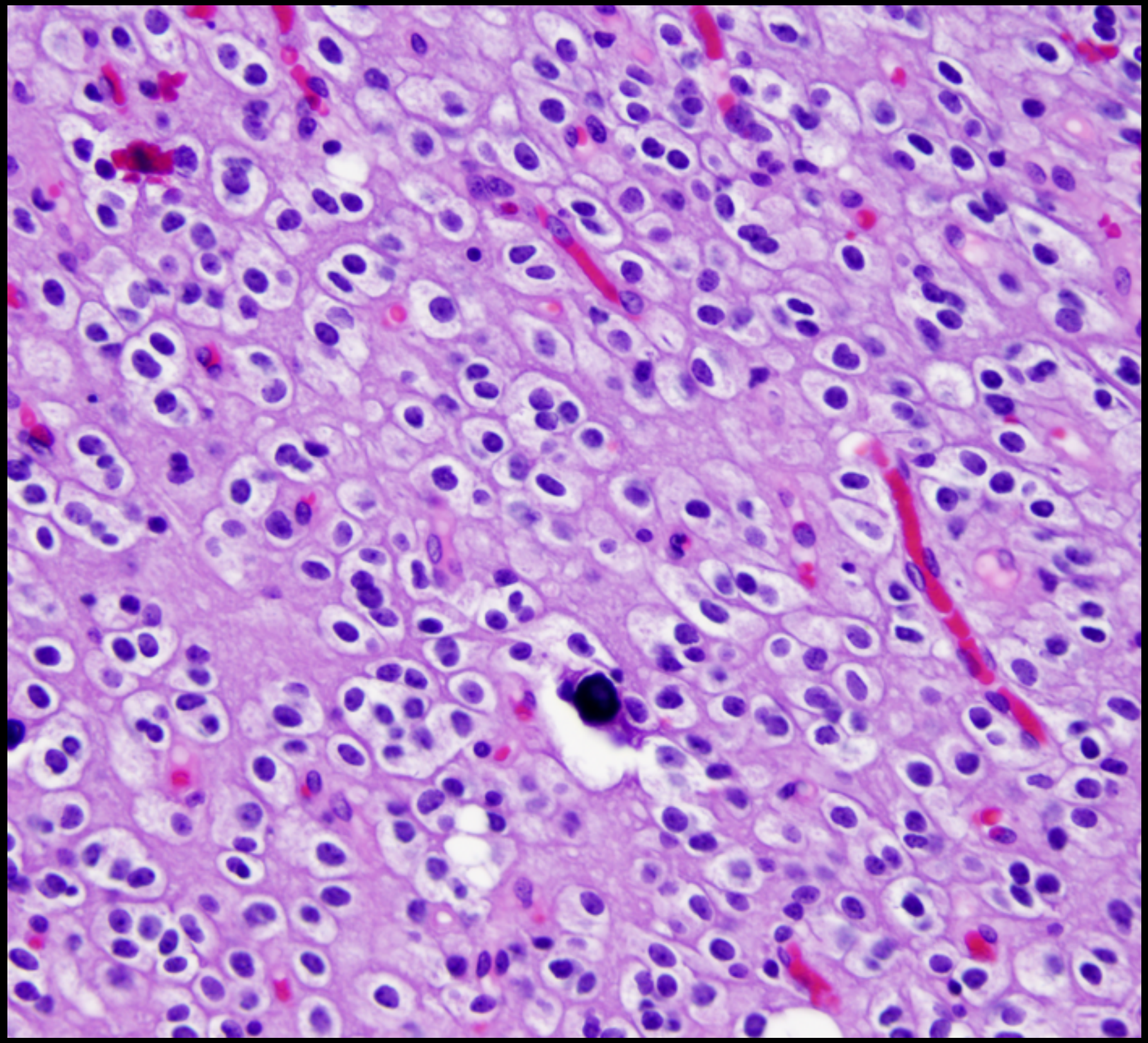

OLIGODENDROGLIOMA

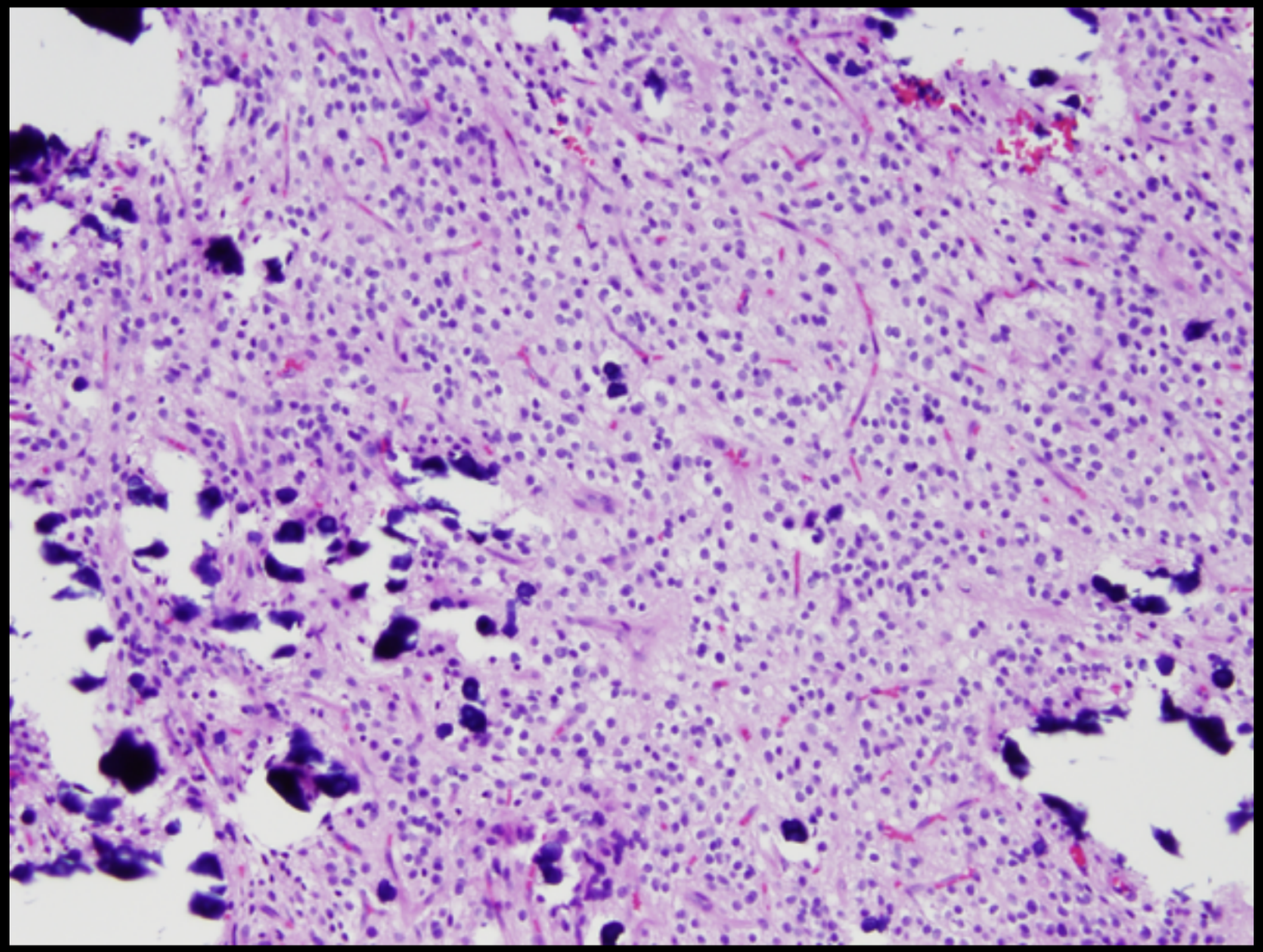

RMI

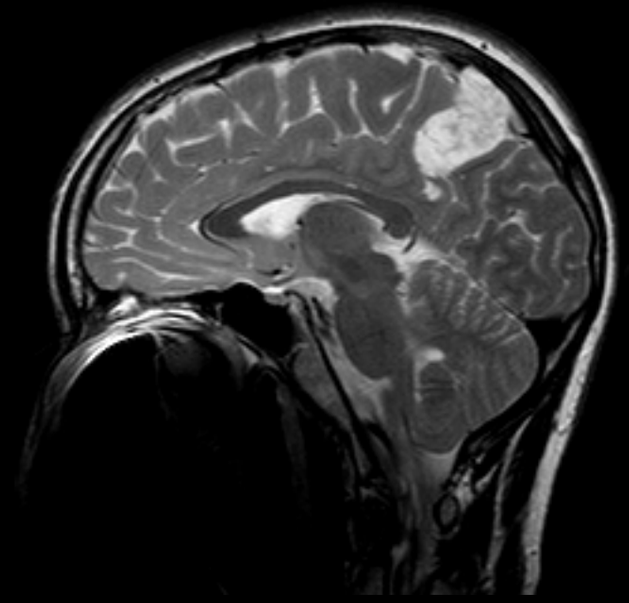

MICROCALCIFICACIONES Y VASOS MICROVASCULATURA

ASTROCITOMA PILOCITICO (AP)

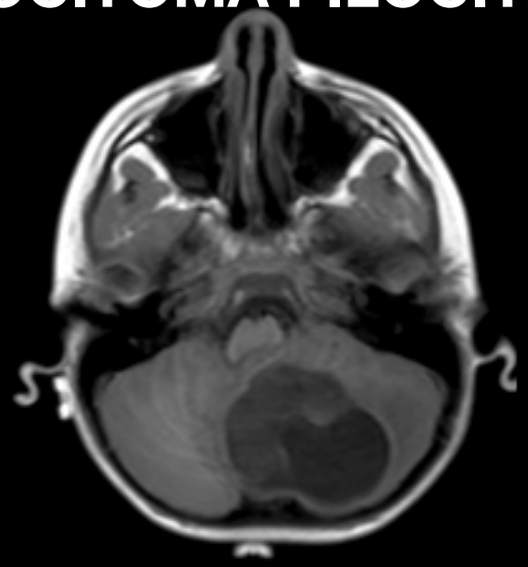

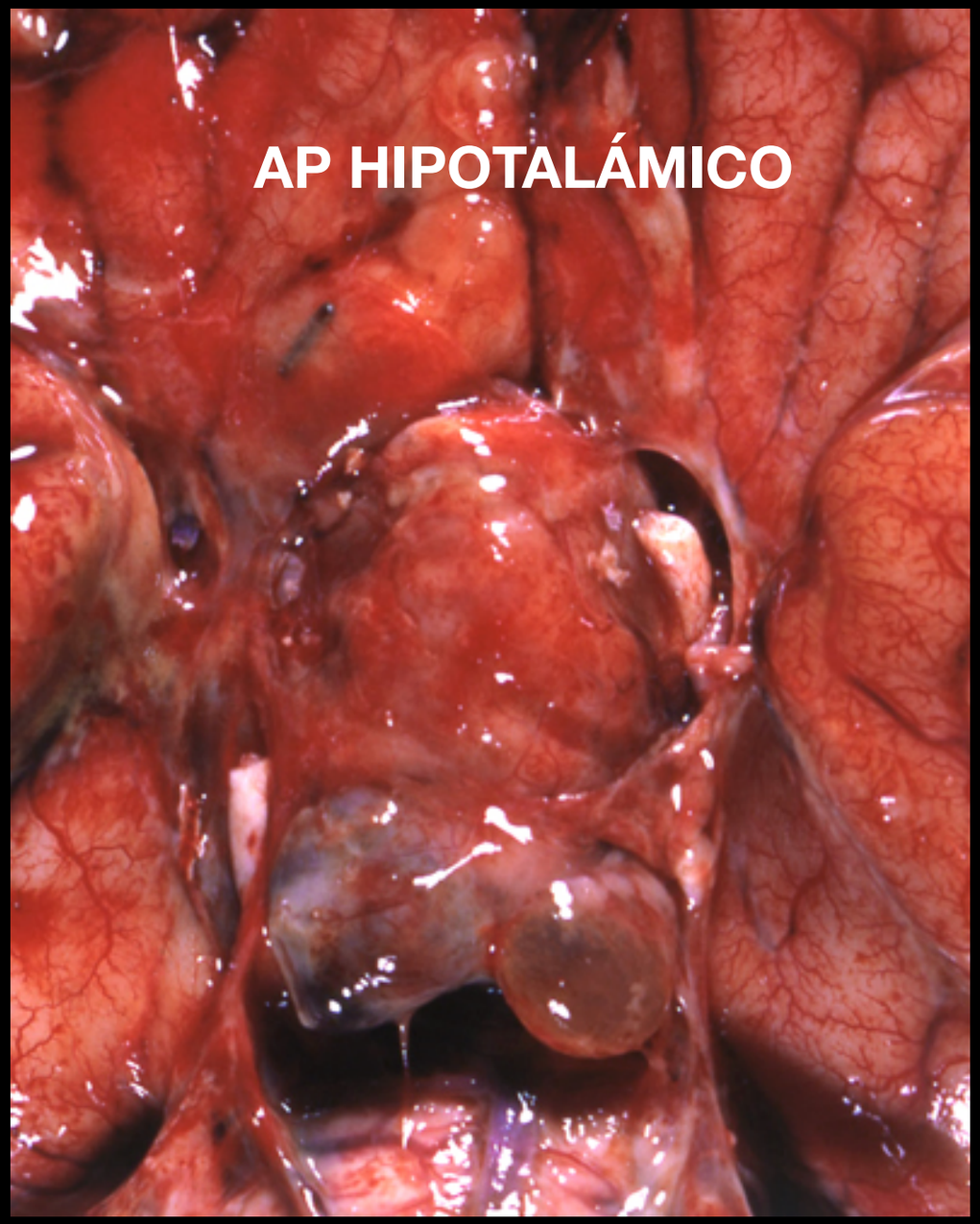

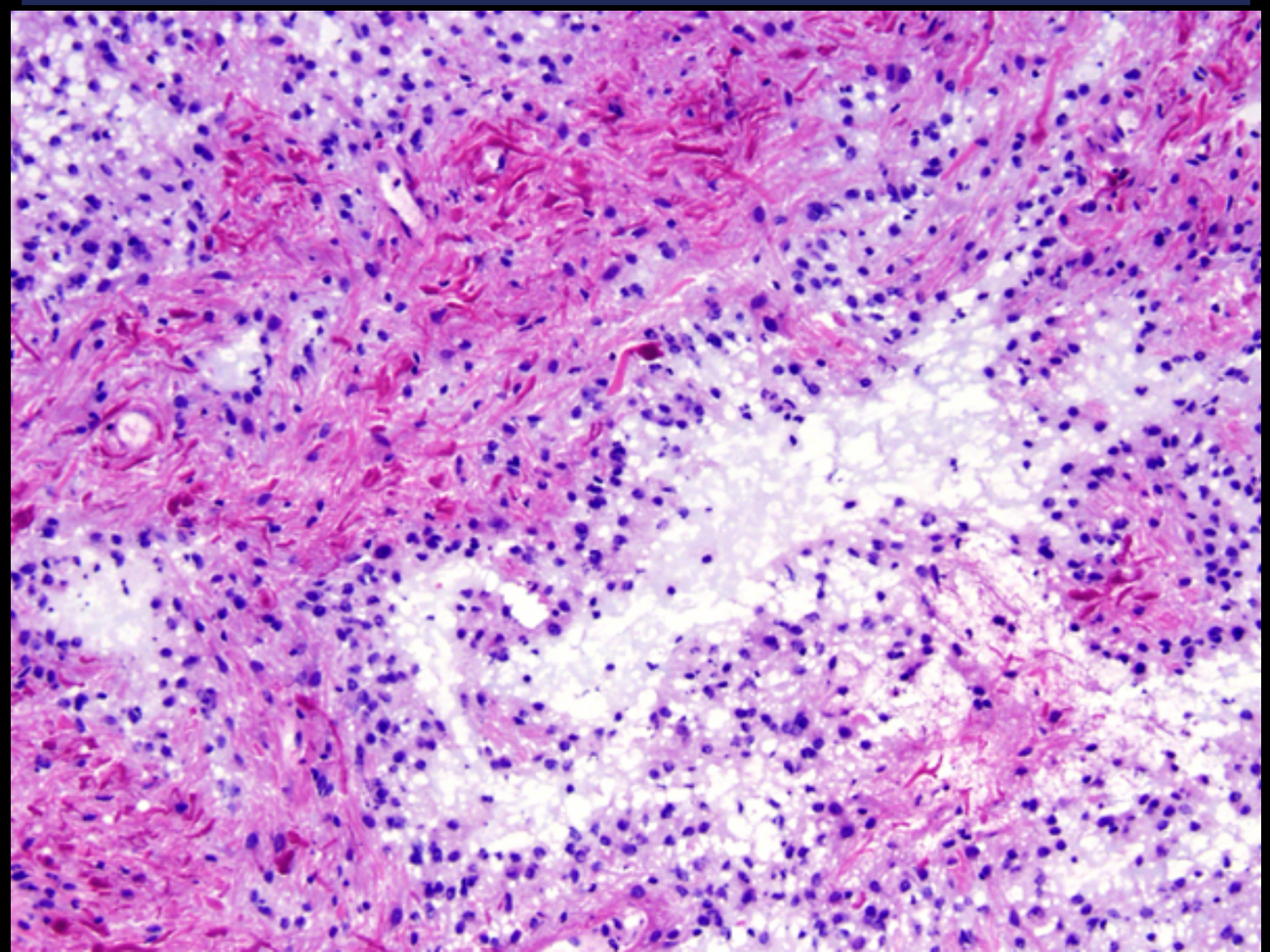

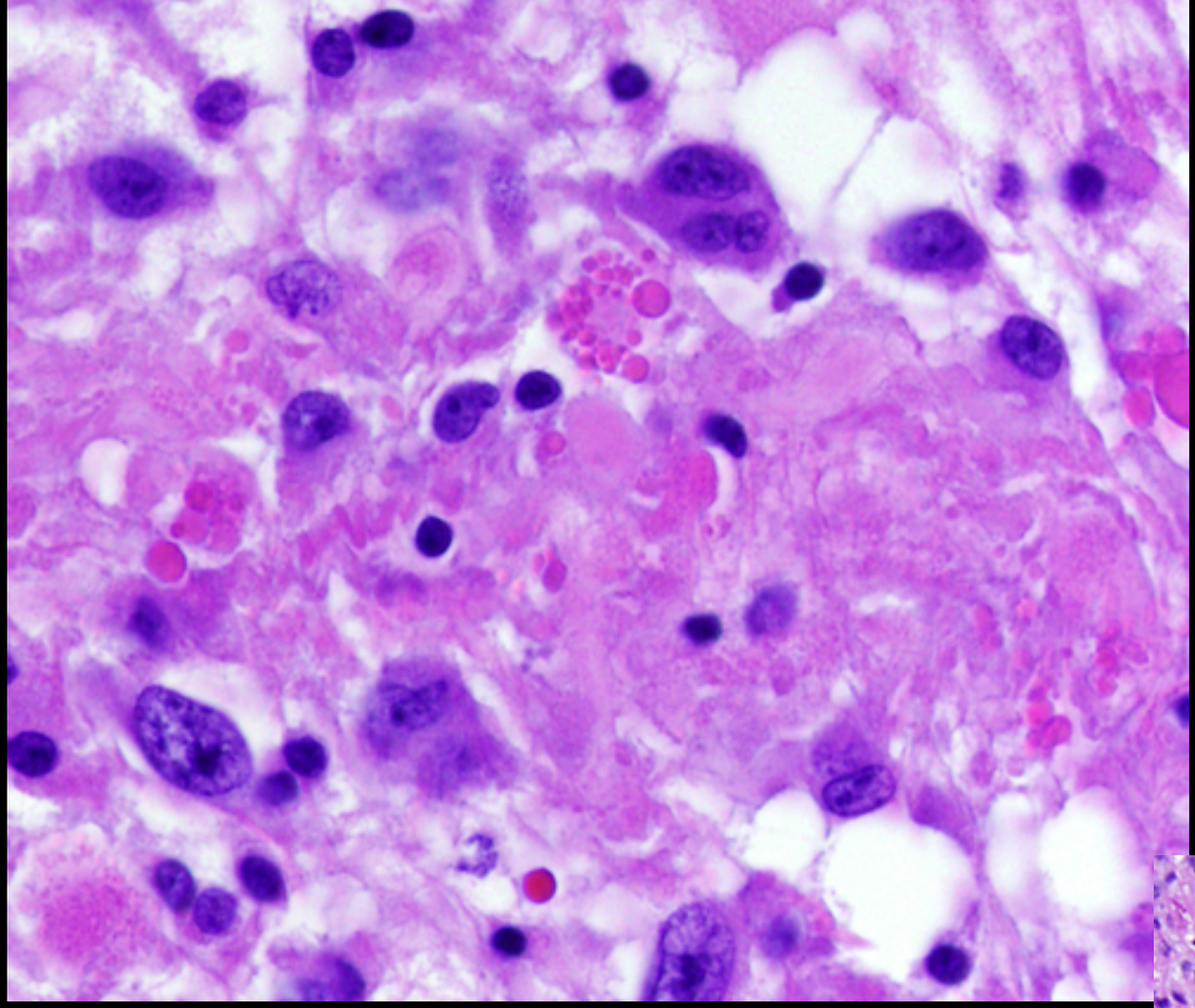

AP
ABUNDANTES FIBRAS DE ROSENTHAL

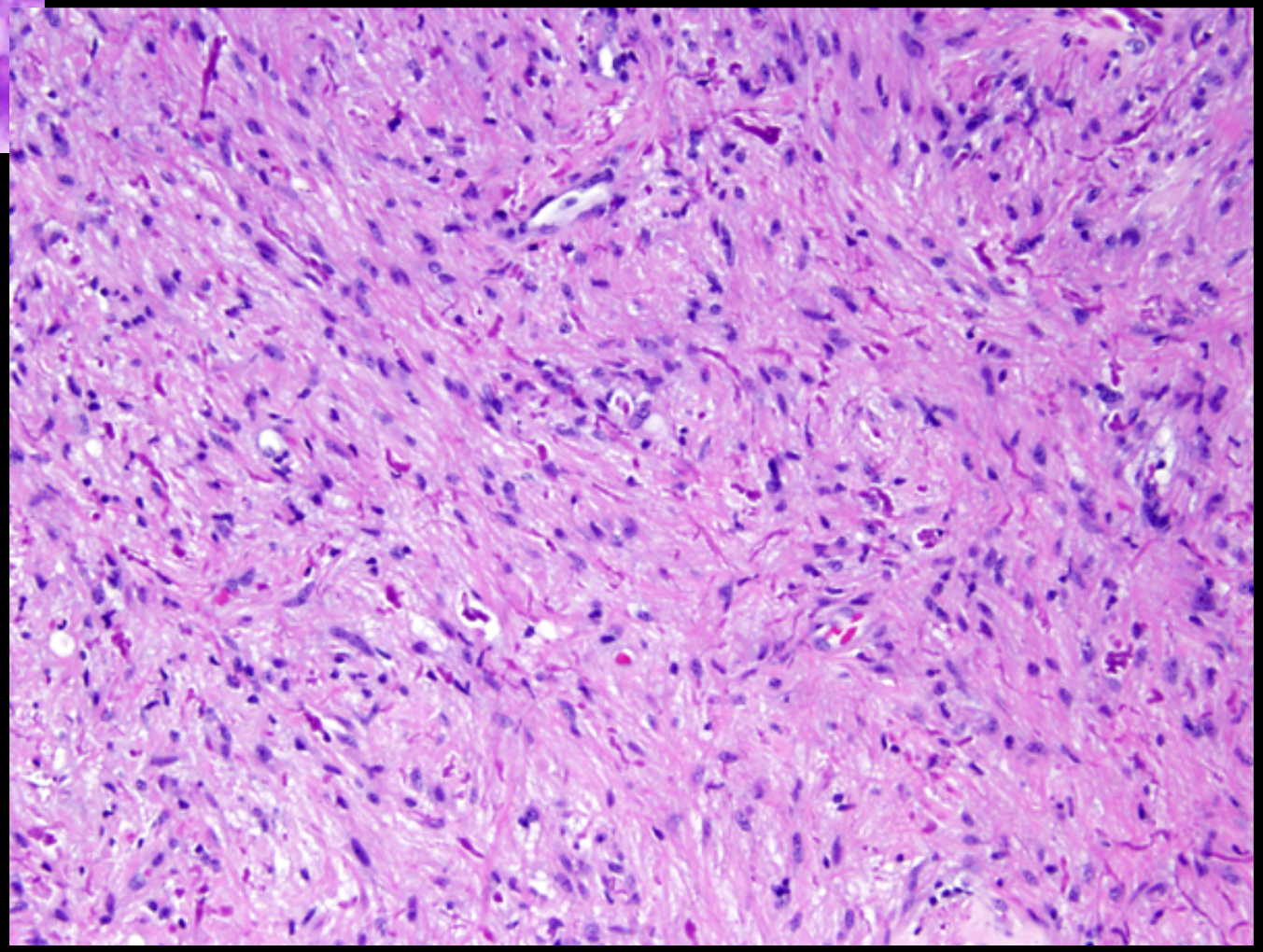

XANTOASTROCITOPMA PLEOMÓRFICO

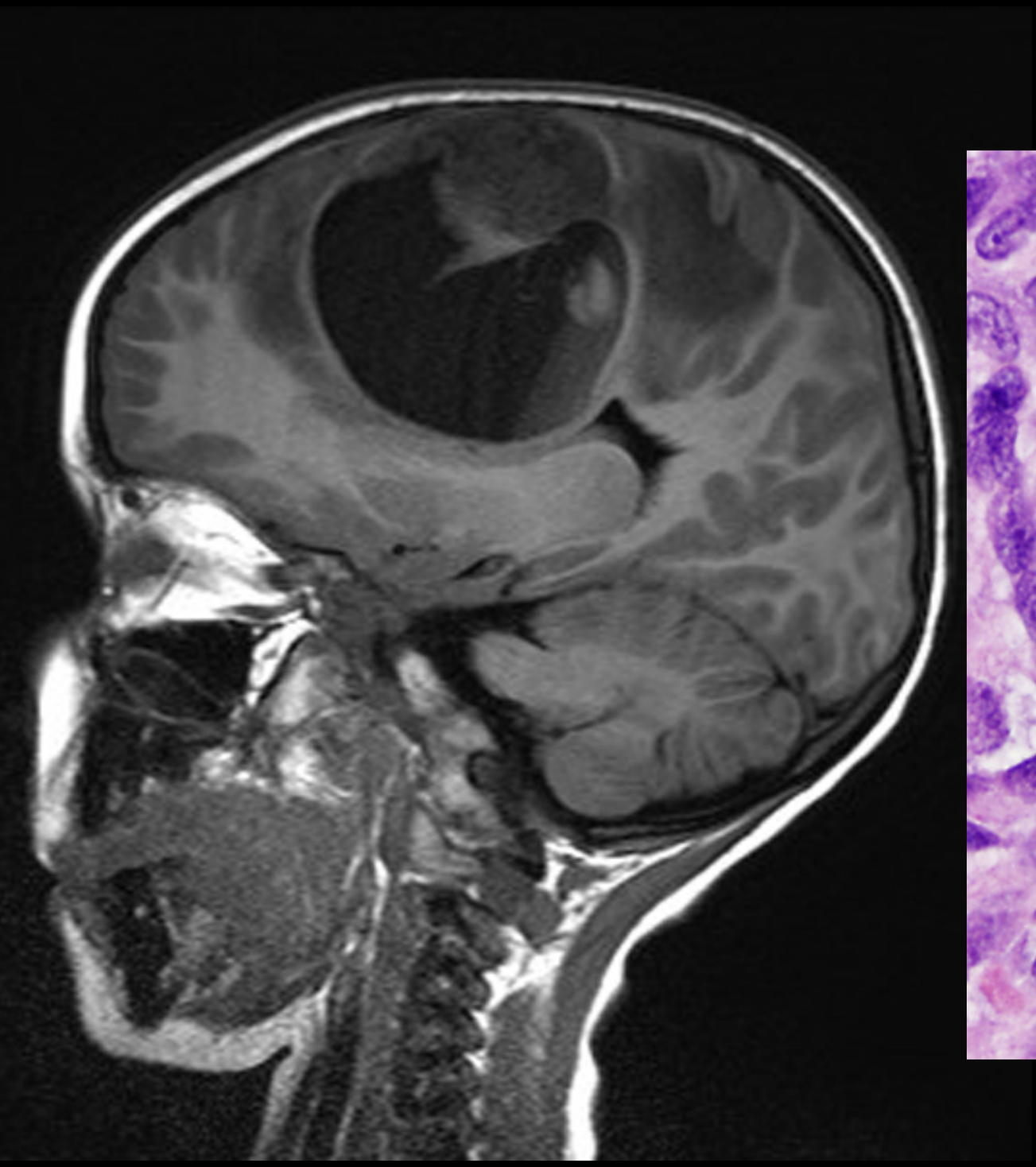

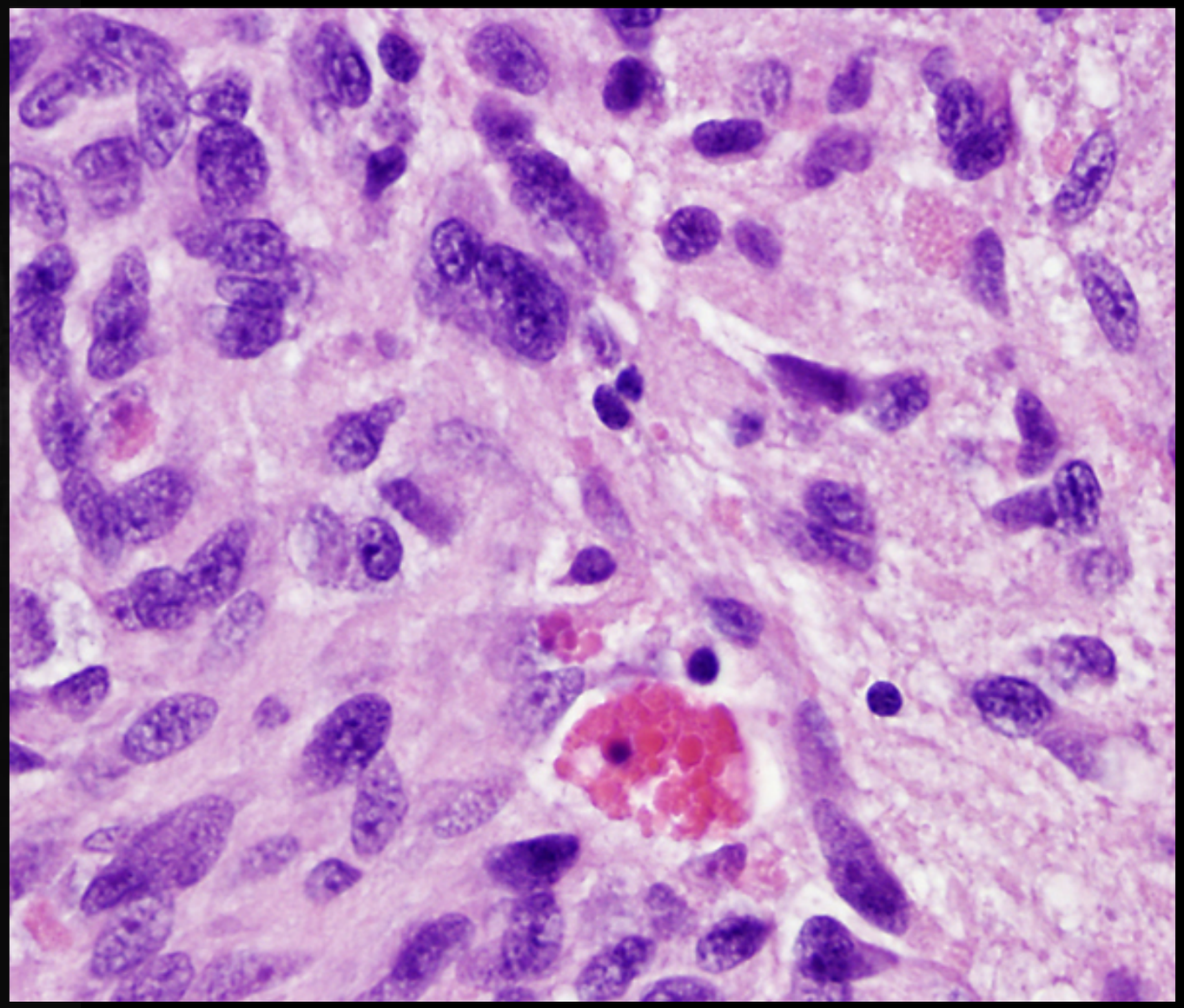

XANTOASTROCITOMA PLEOMÓRFICO

GRADO II DE LA WHO

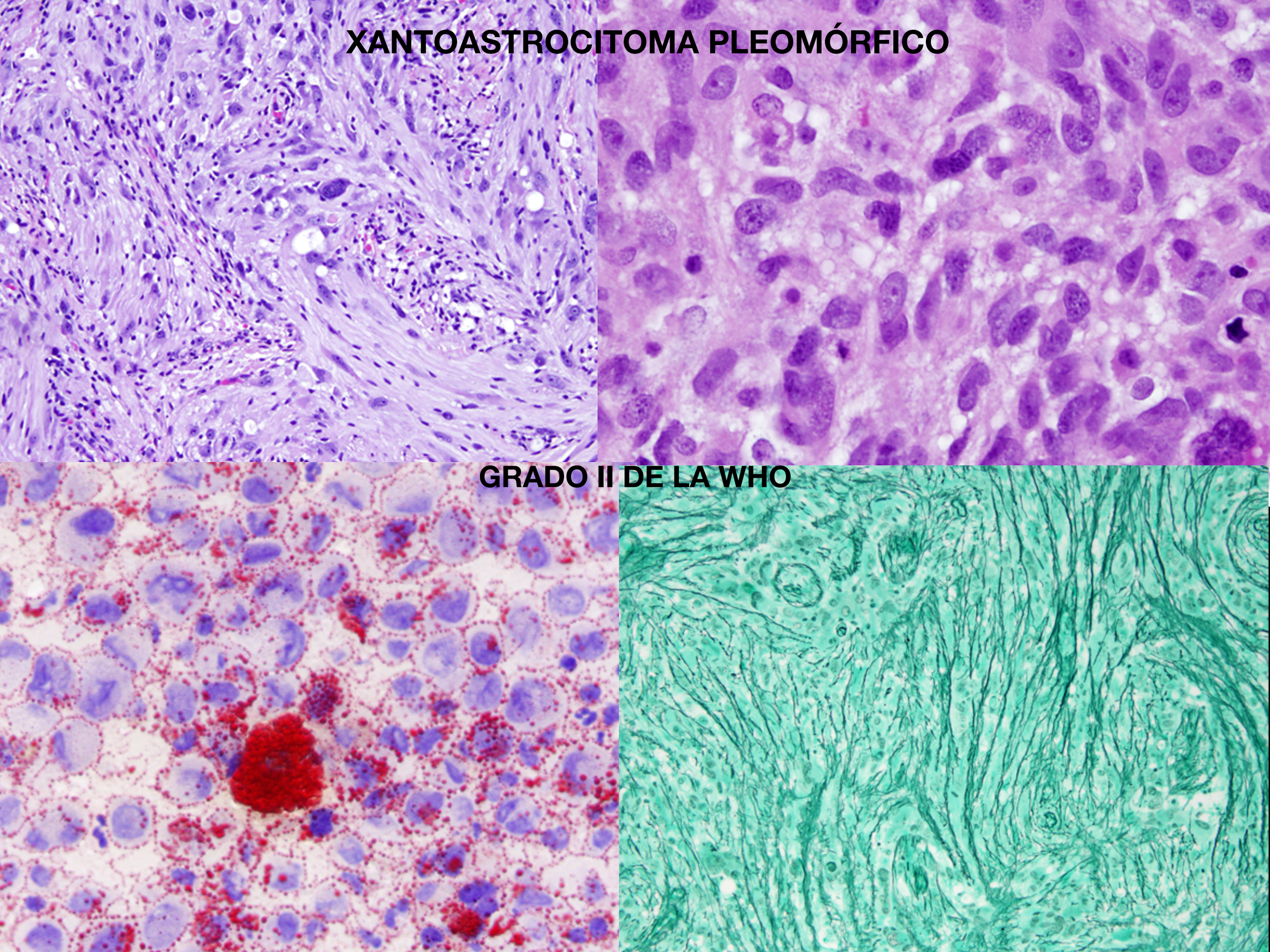

GLIOMAS DE LA LÍNEA MEDIA DIFUSOS

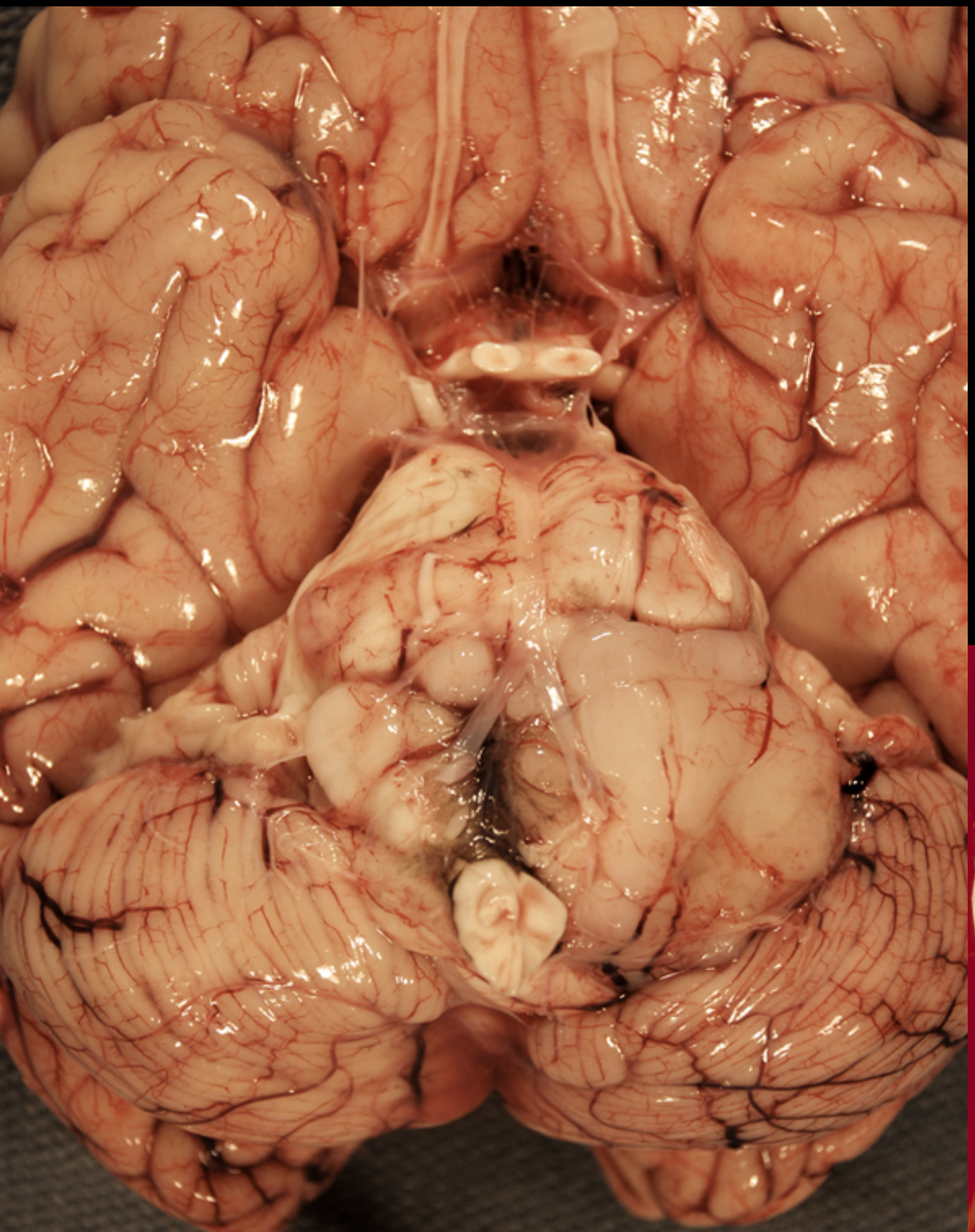

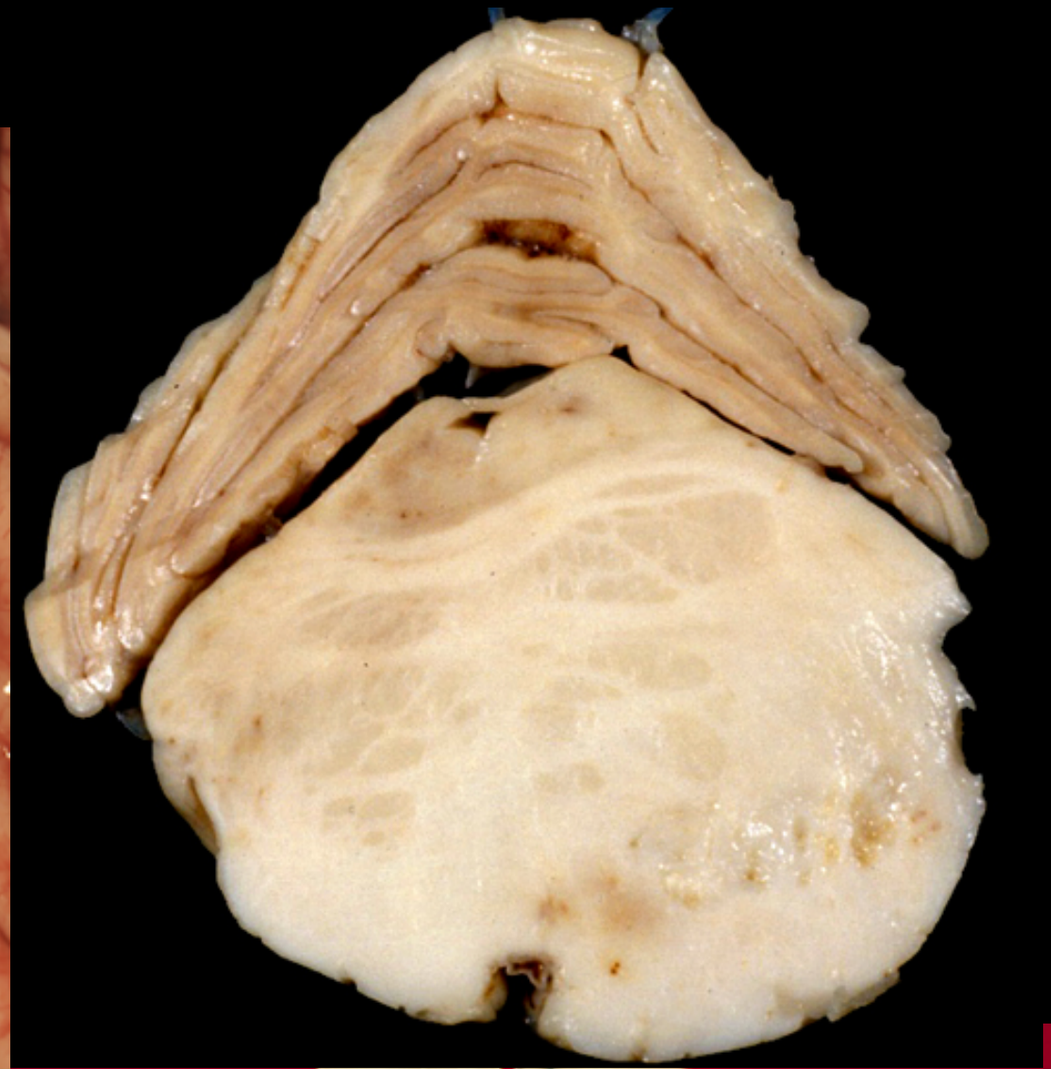

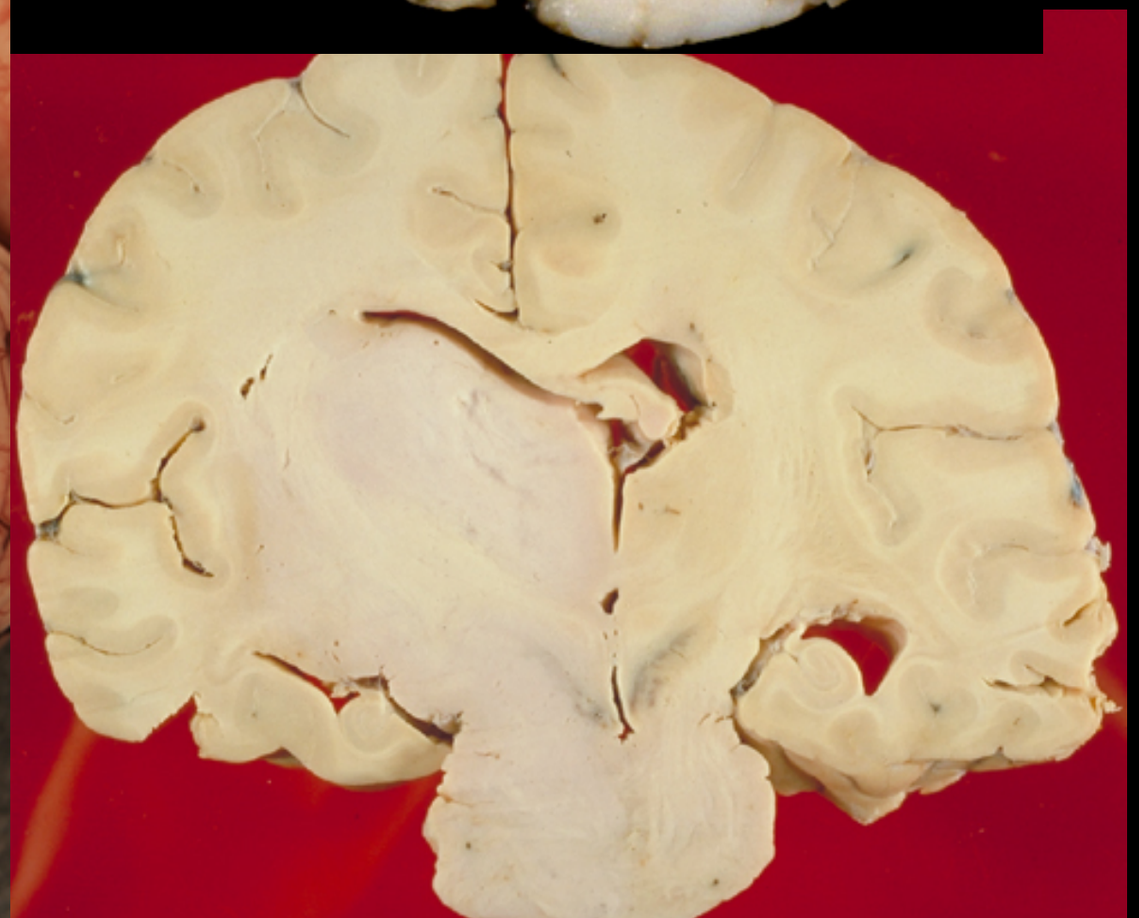

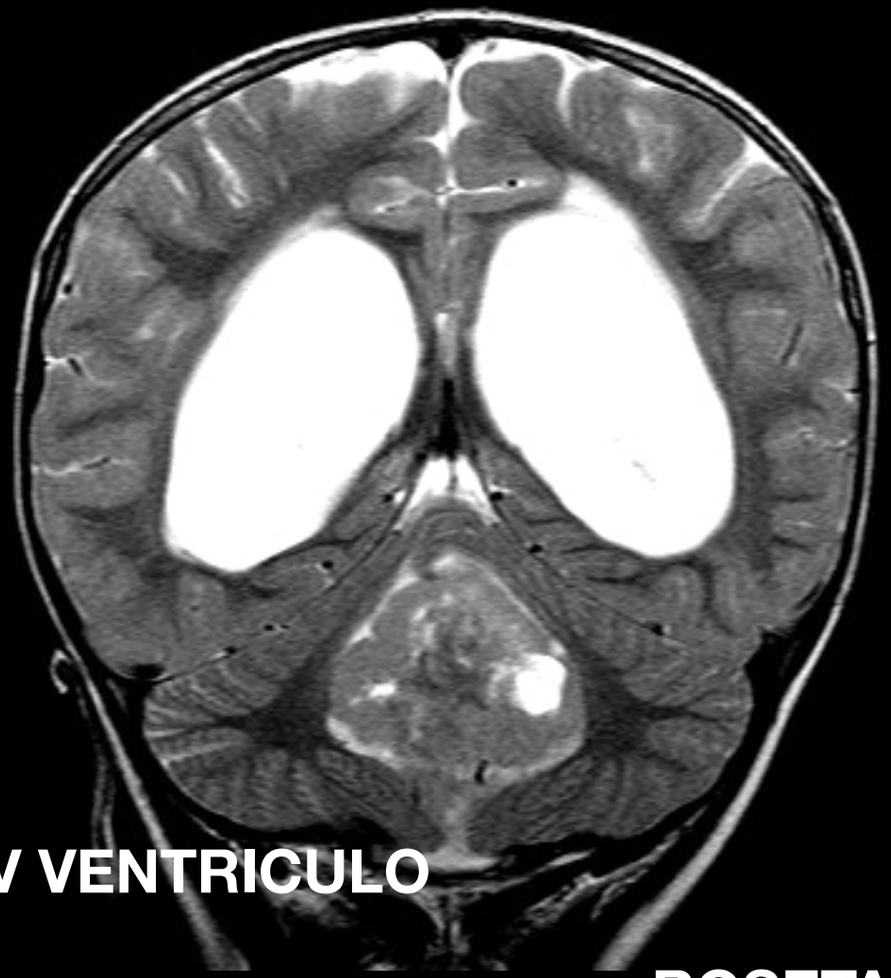

EPENDIMOMA DEL IV VENTRICULO

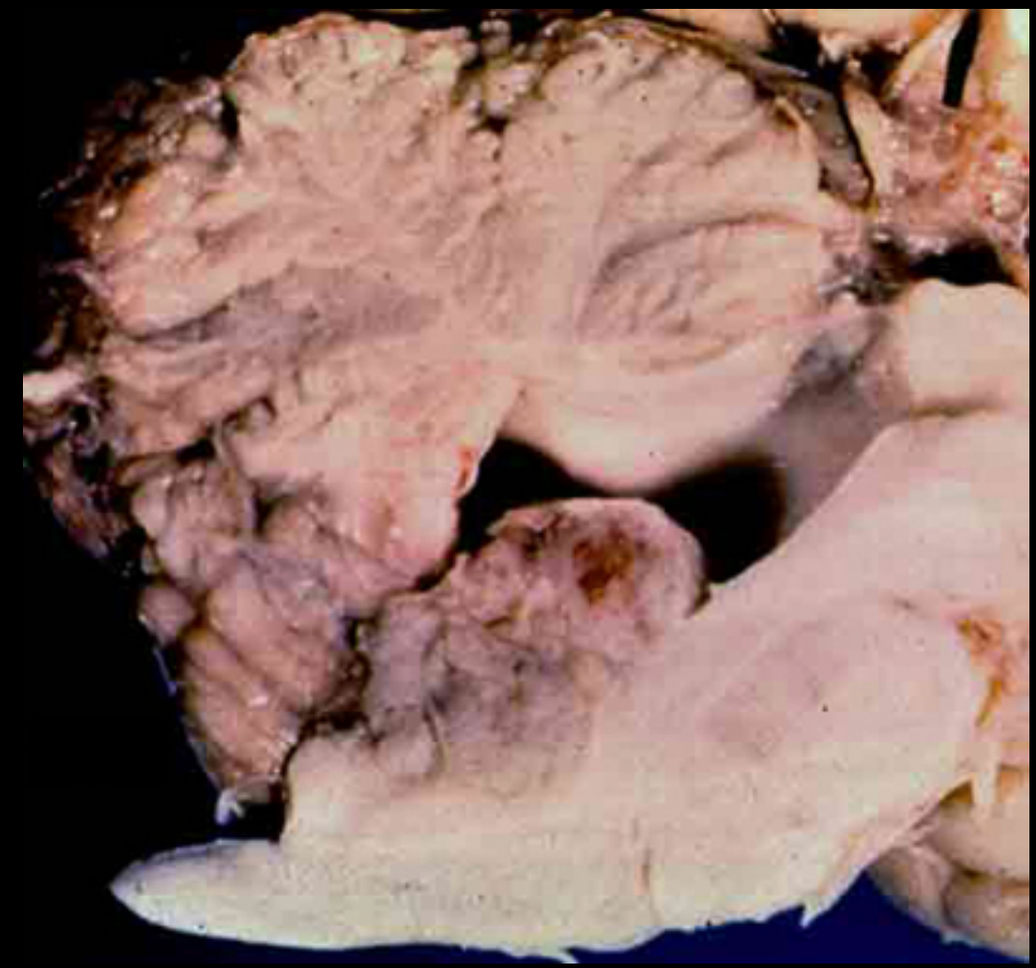

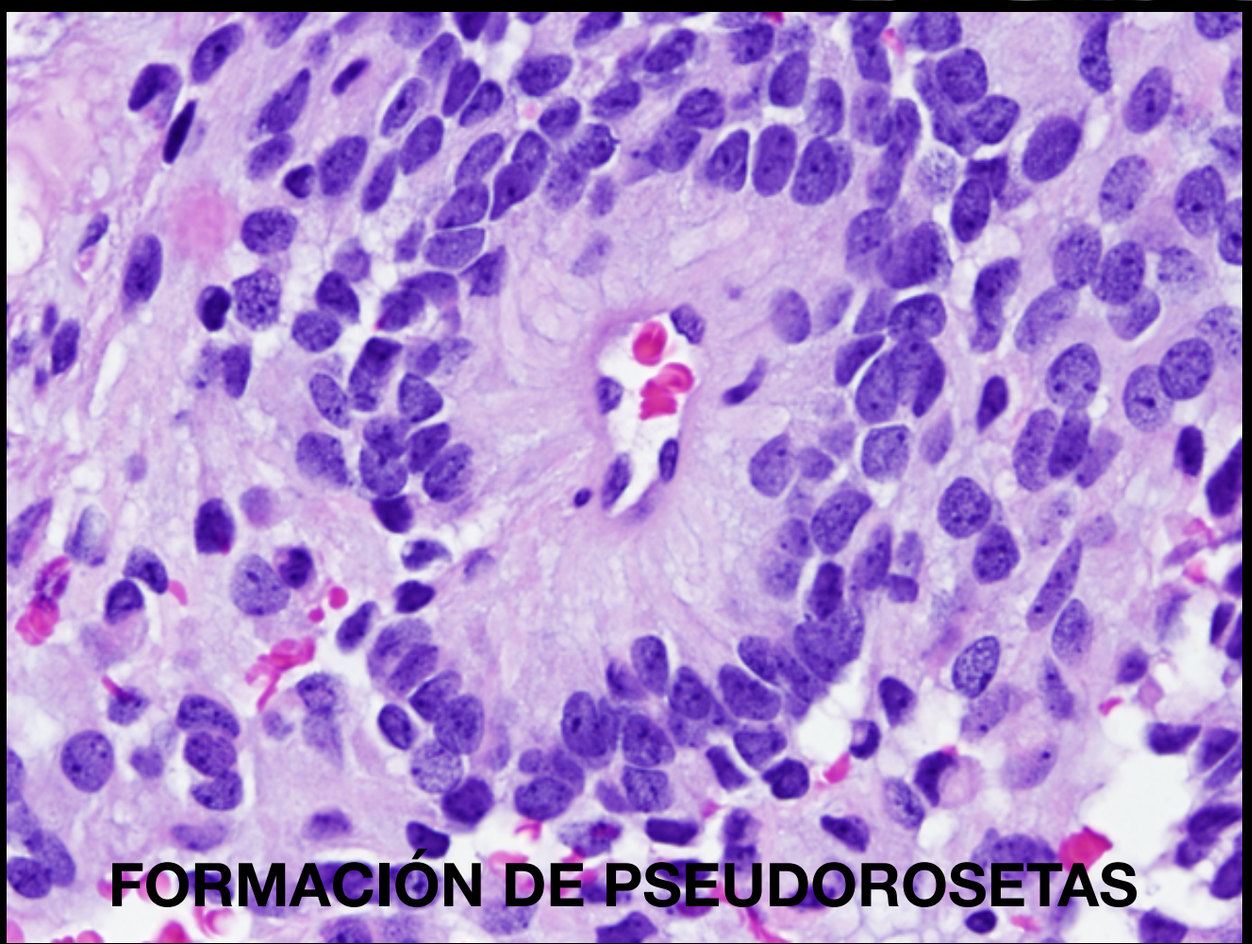

FORMACIÓN DE PSEUDOROSETAS

ROSETAS VERDADERAS DE EPENDIMOMA

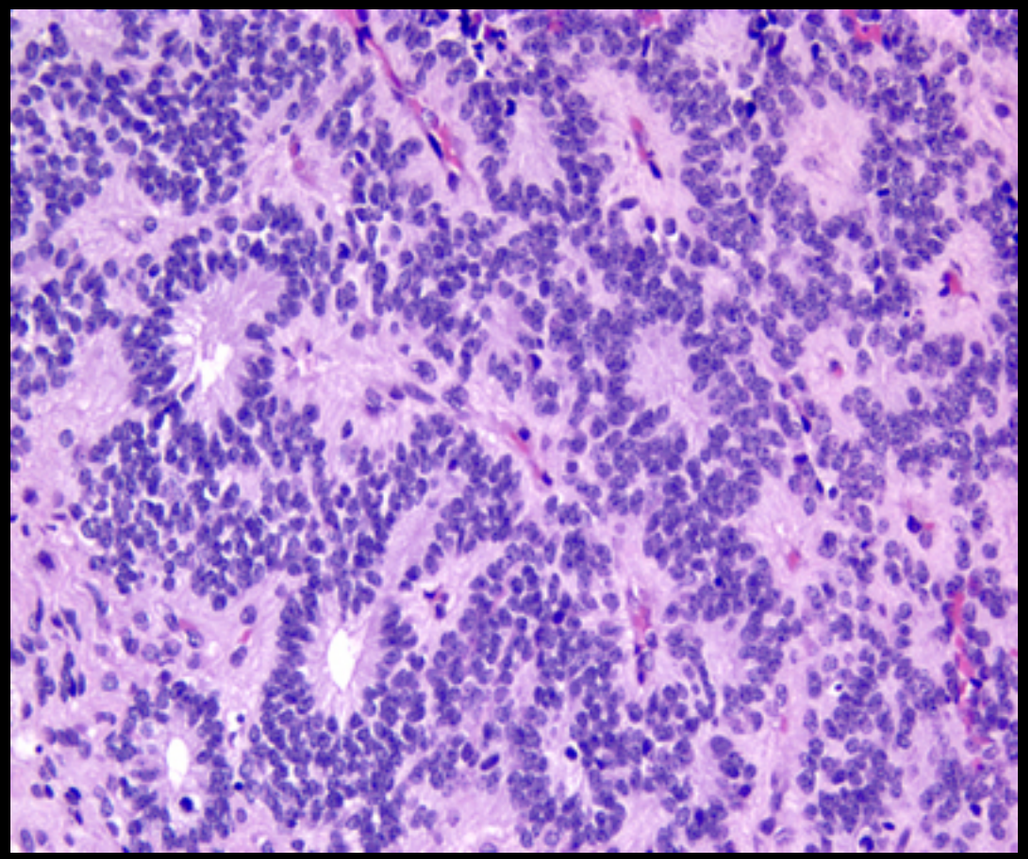

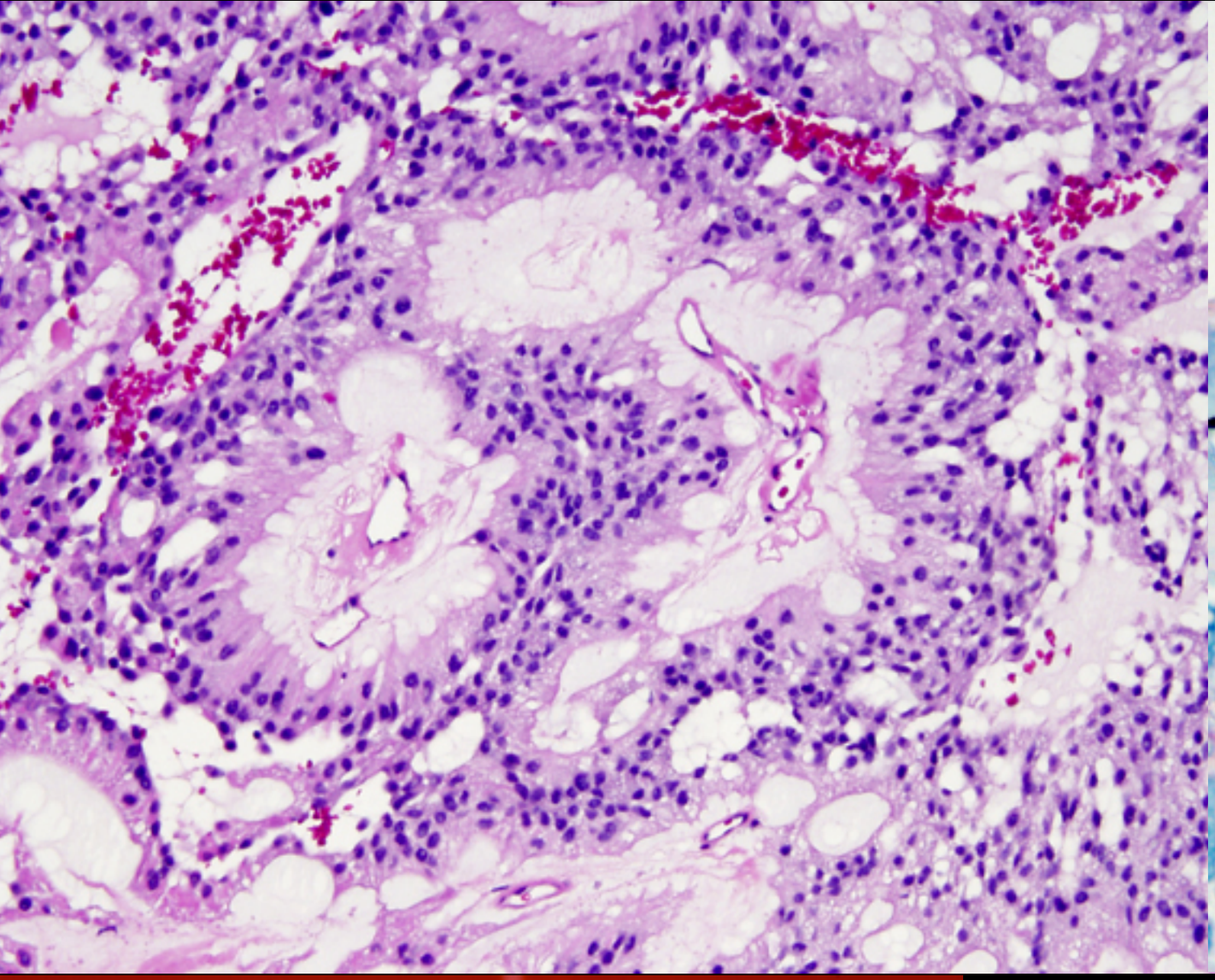

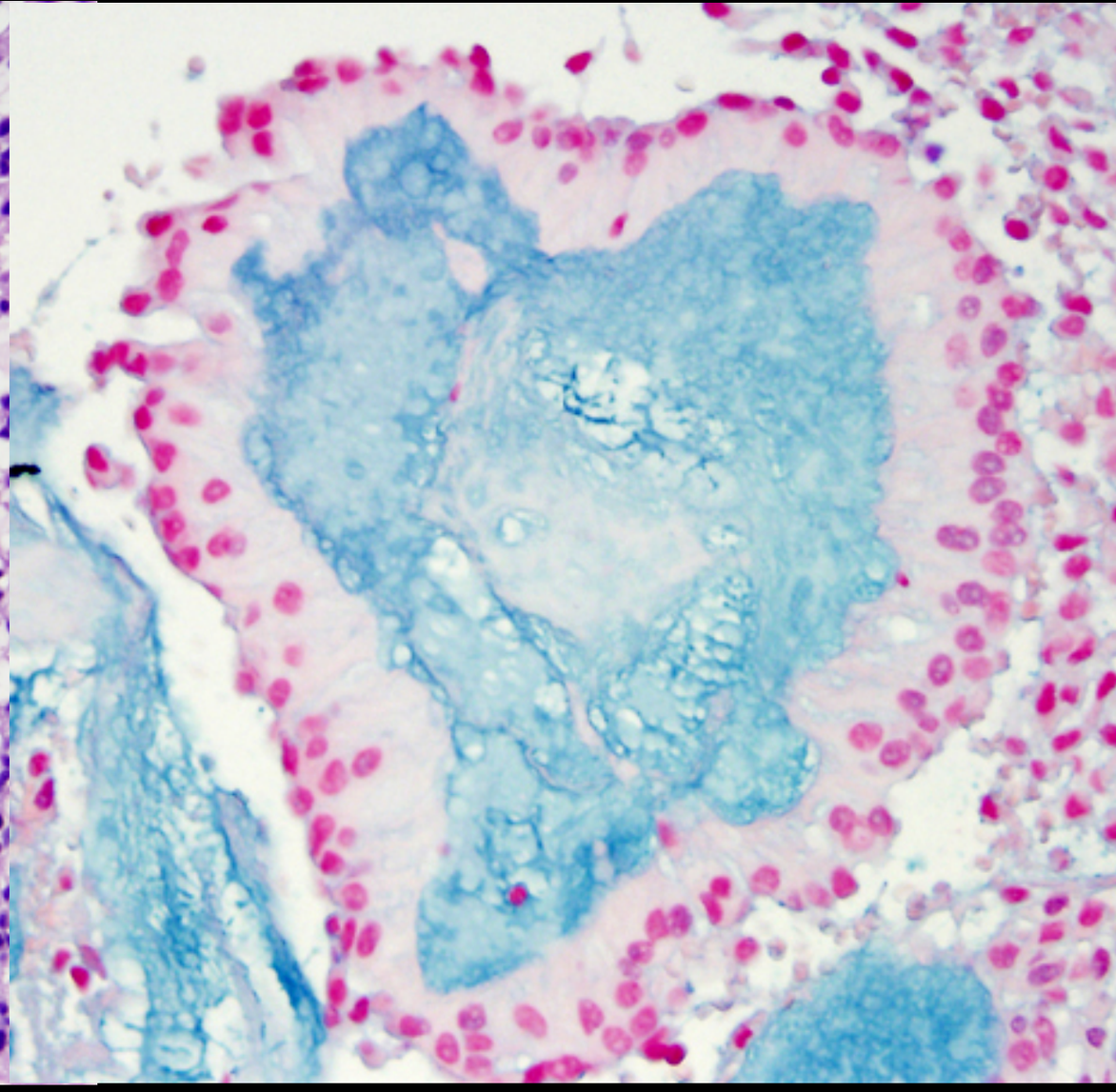

EPENDIMOMA MIXOPAPILAR (MUCINA)

SUBEPENDIMOMA (INTRAVENTRICULAR)

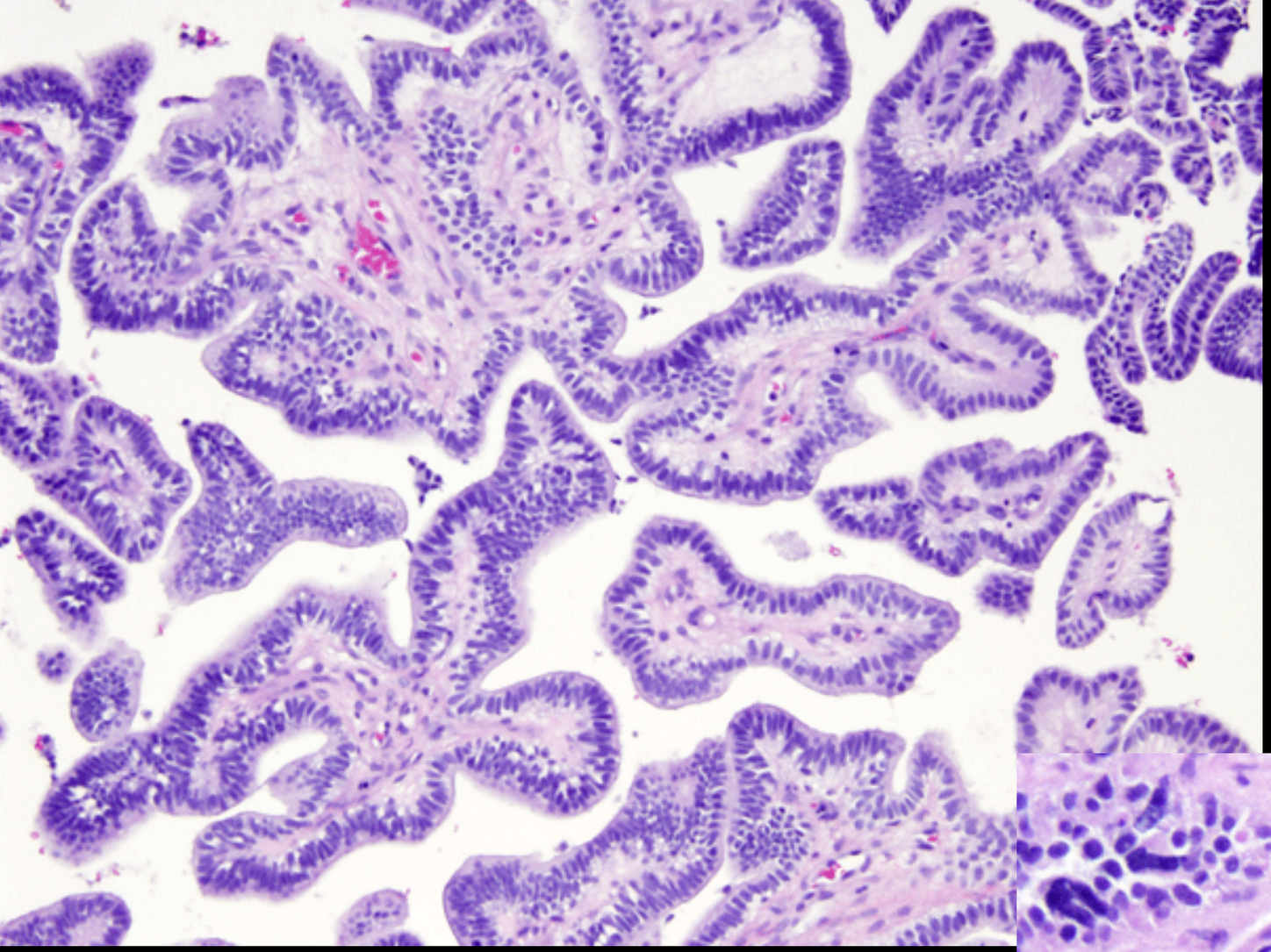

PAPILOMA DE PLEXOS COROIDES

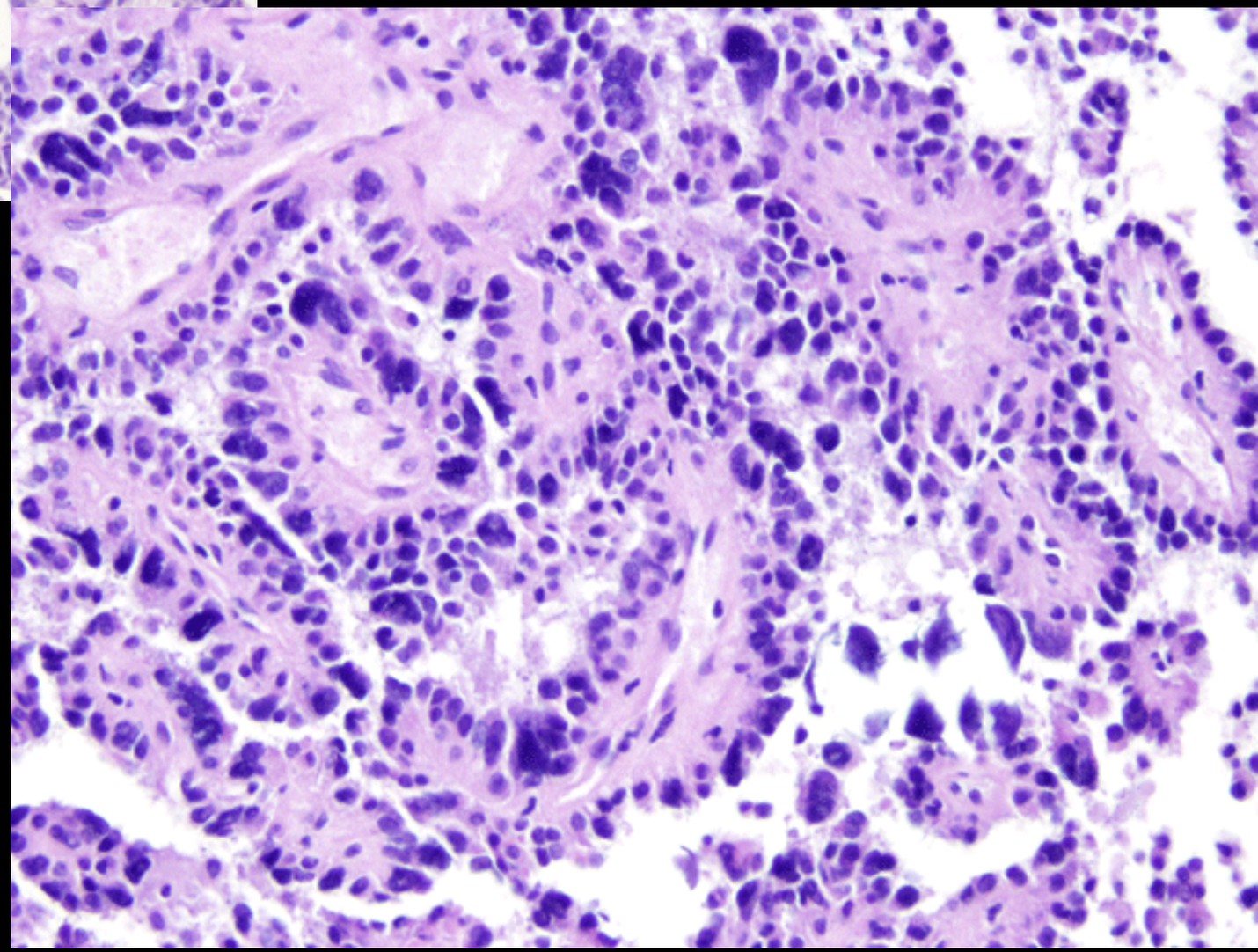

CARCINOMA DE PLEXOS COROIDES

CAPA GRANULAR EXTERNA DEL CEREBELO (ORIGEN DE LOS MEDULOBLASTOMAS)

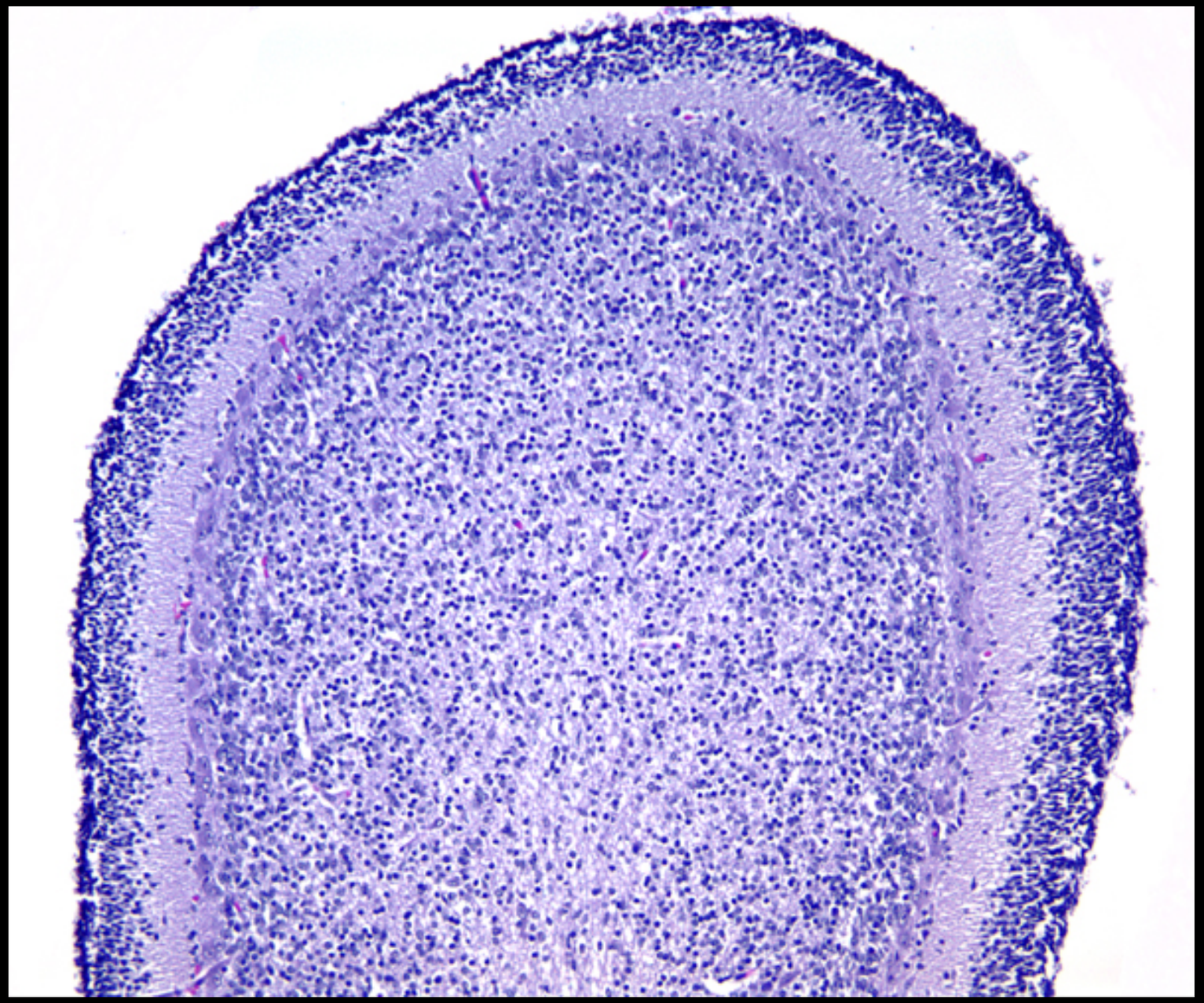

MEDULOBLASTOMA

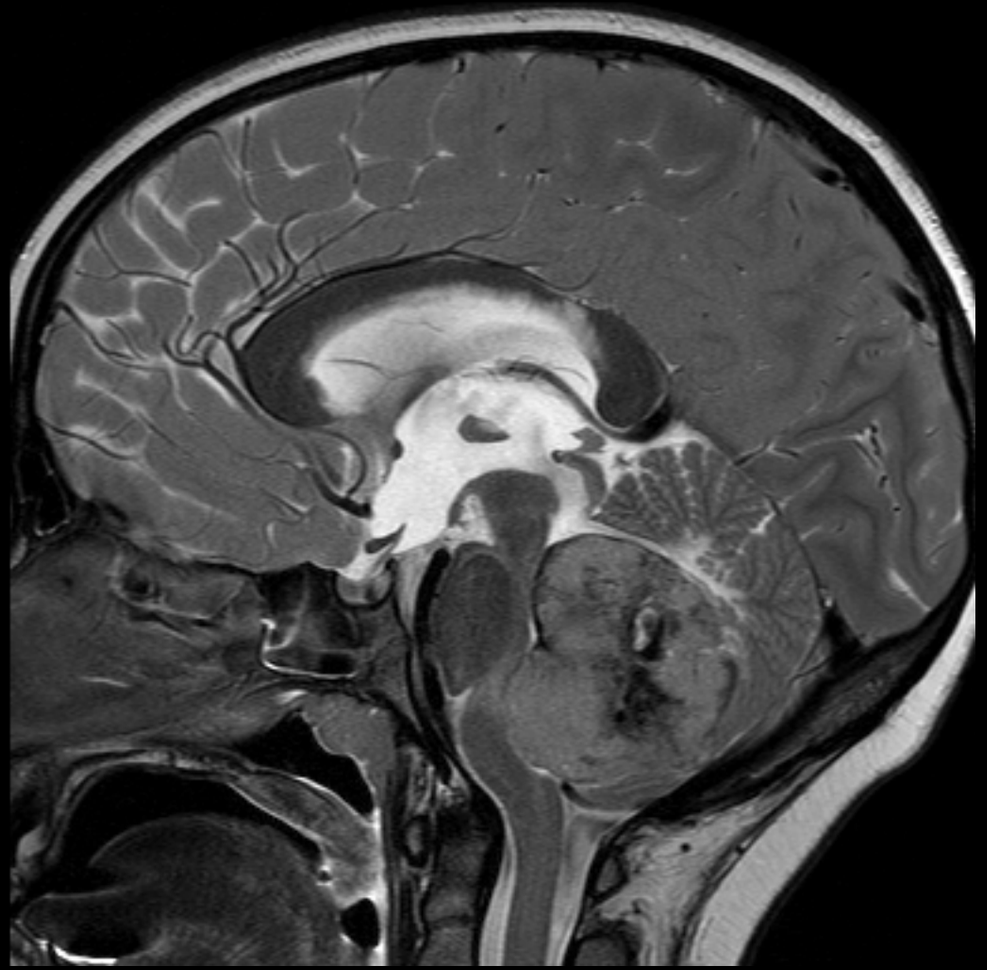

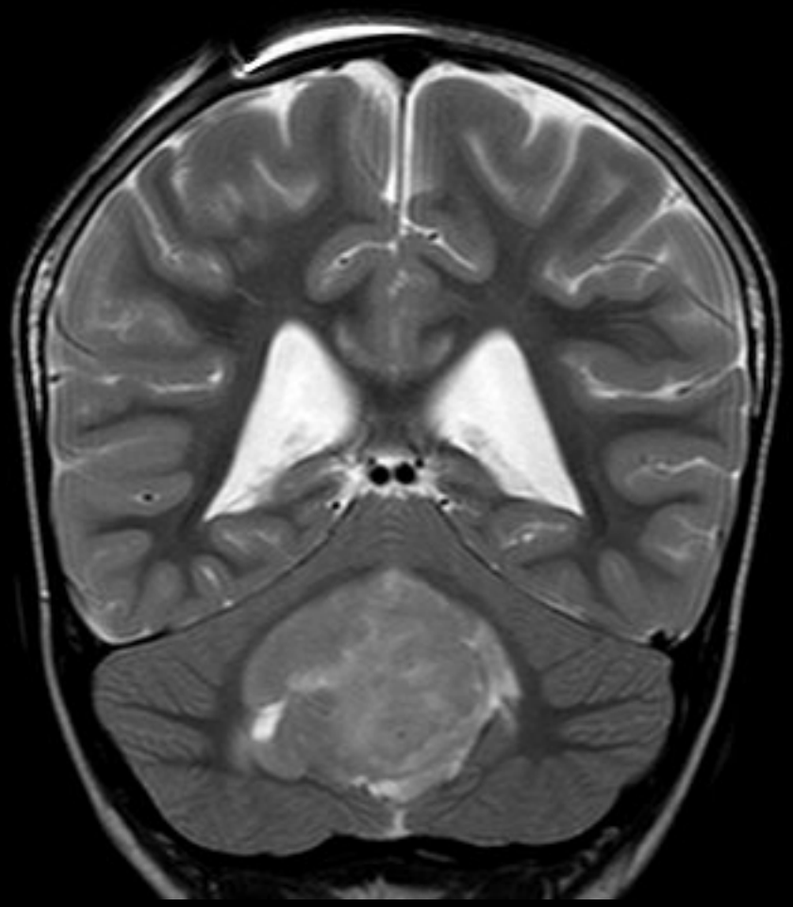

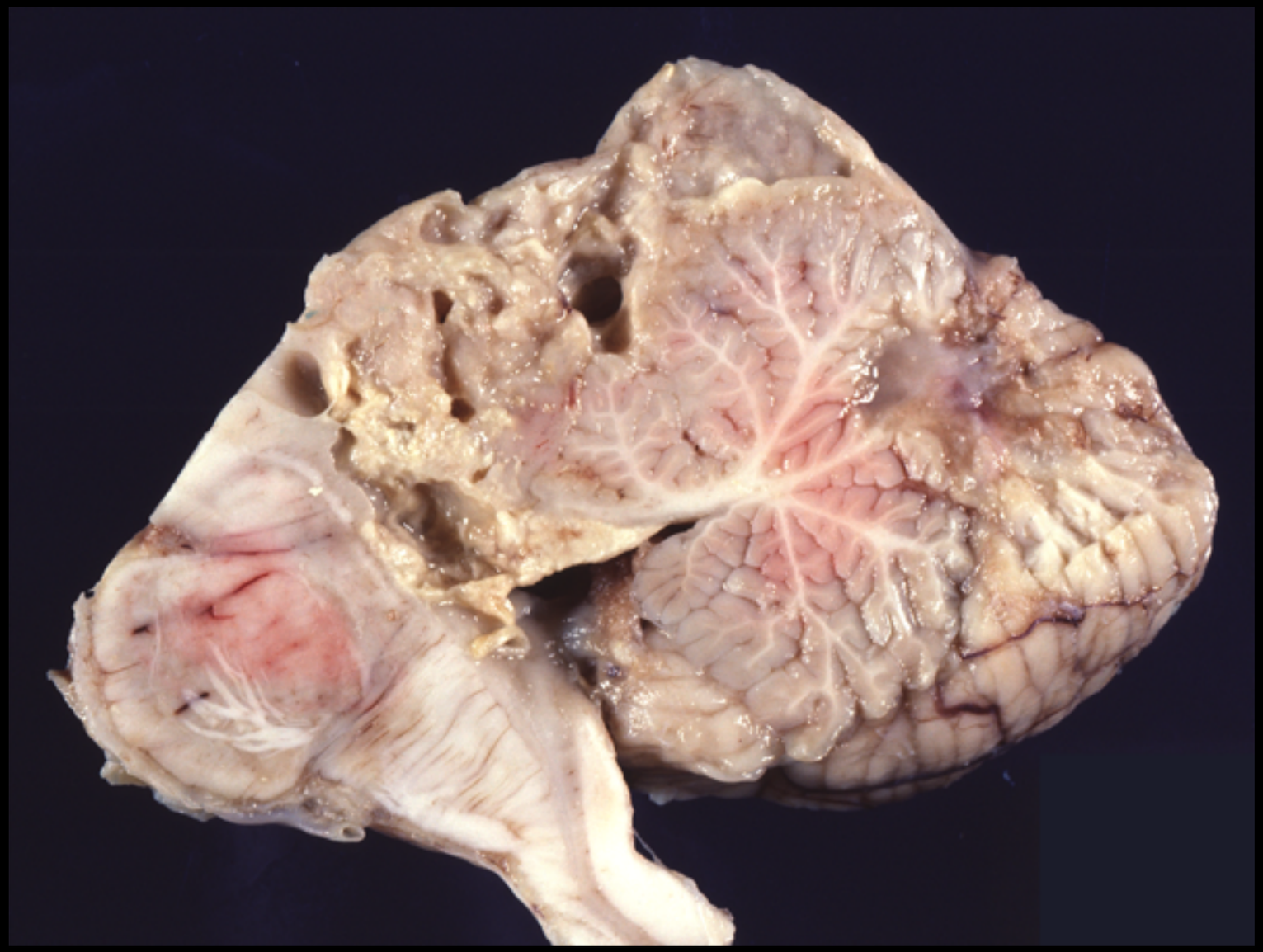

MEDULOBLASTOMA CLÁSICO

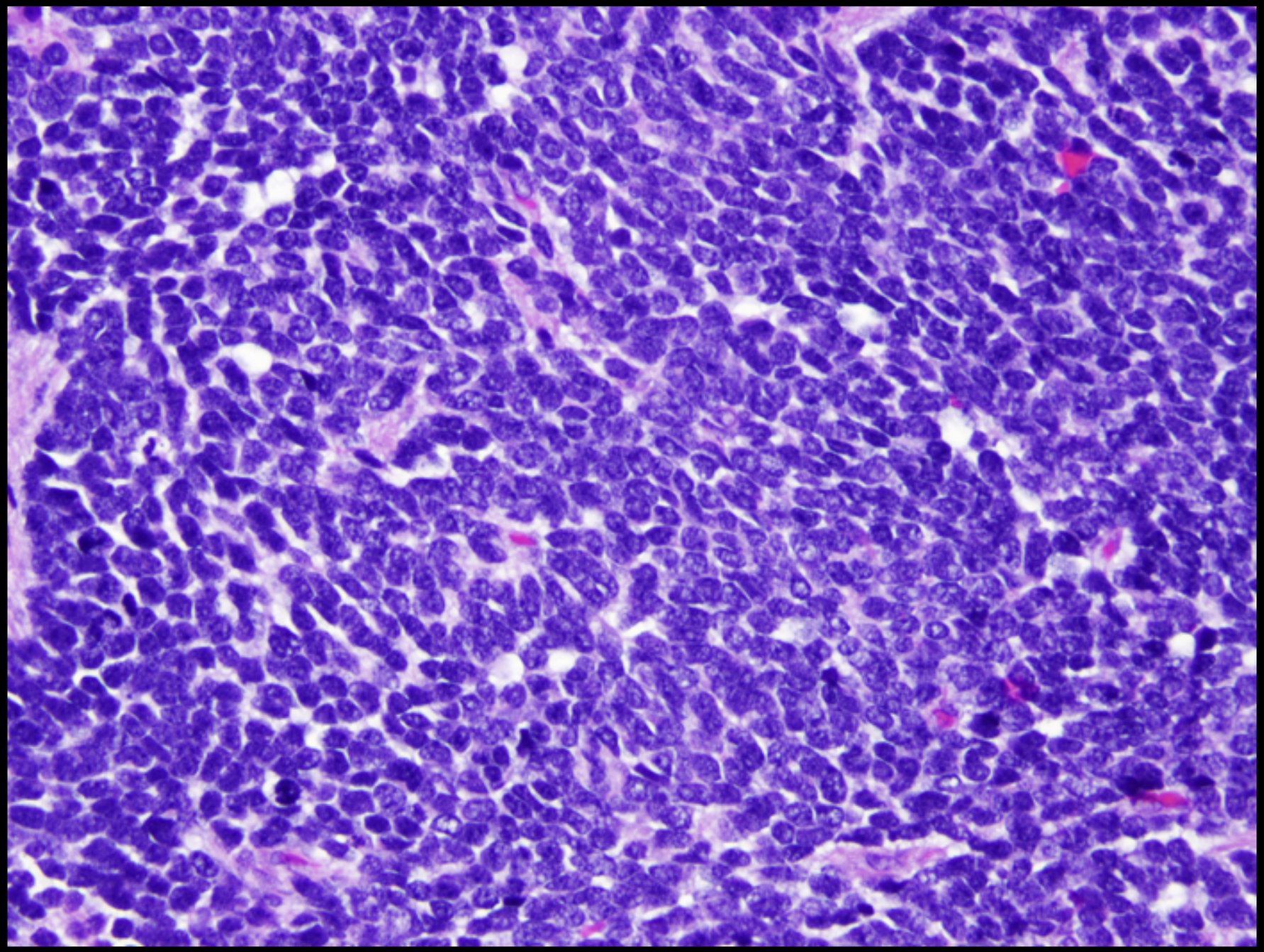

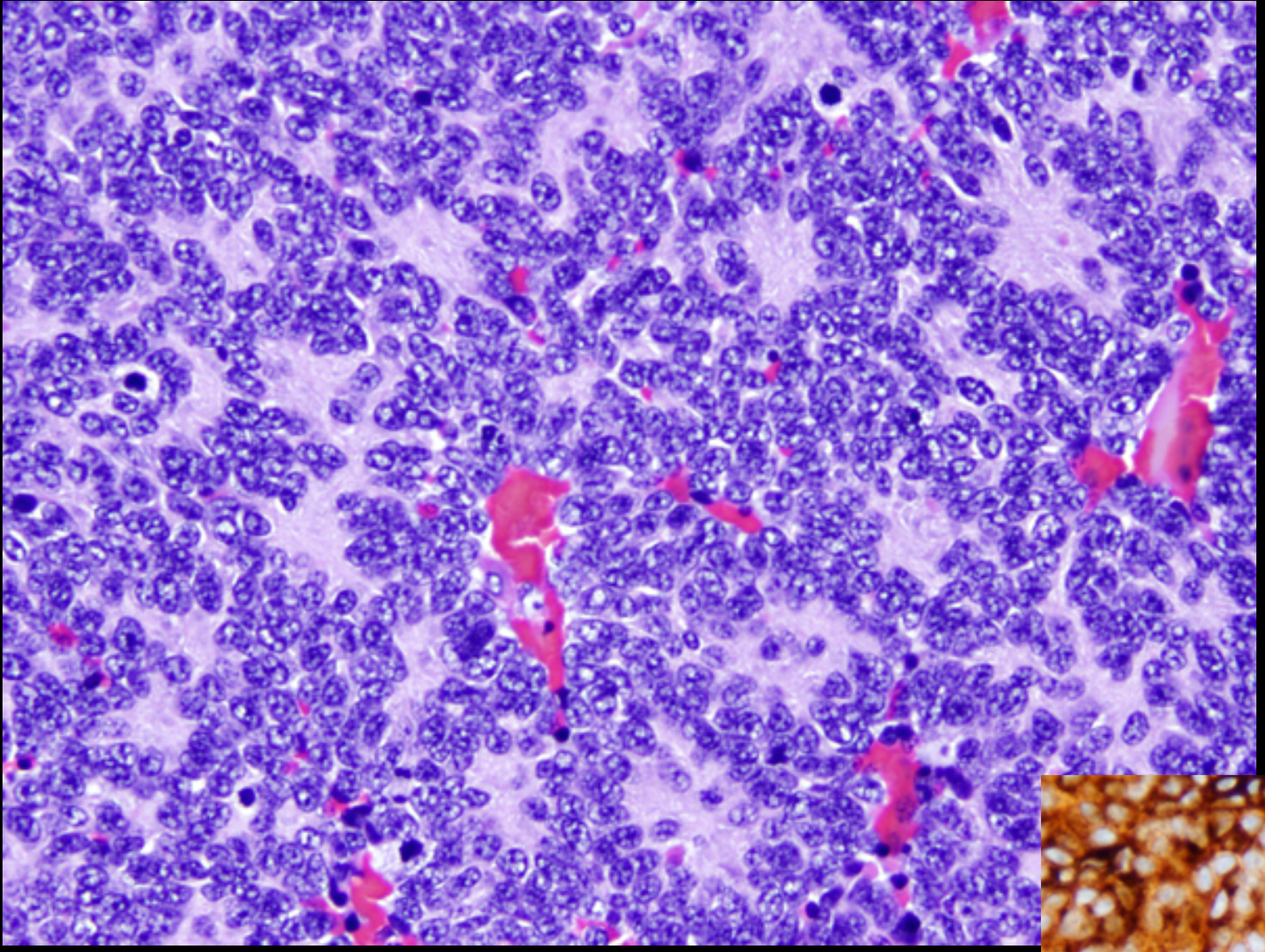

MEDULOBLASTOMA
FORMANDO CLASICAS ROSETAS
DE HOMER -WRIGHT

INMUNOHISTOQUIMICA
POSITIVA PARA SINAPTOFISINA

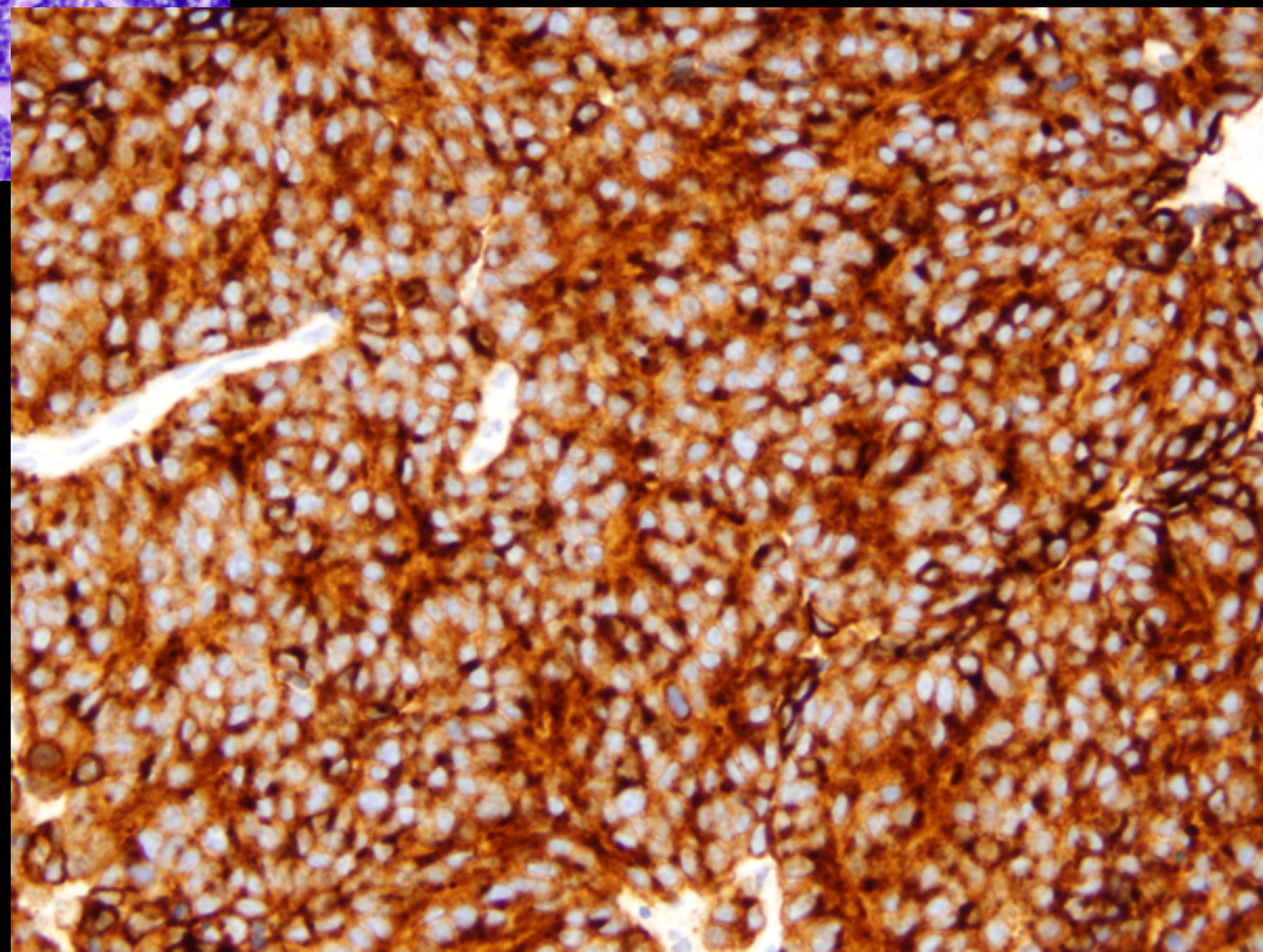

MEDULOBLASTOMA DESMOPLASICO

MEDULOBLASTOMA ANAPLASICO
DE CELULAS GRANDES

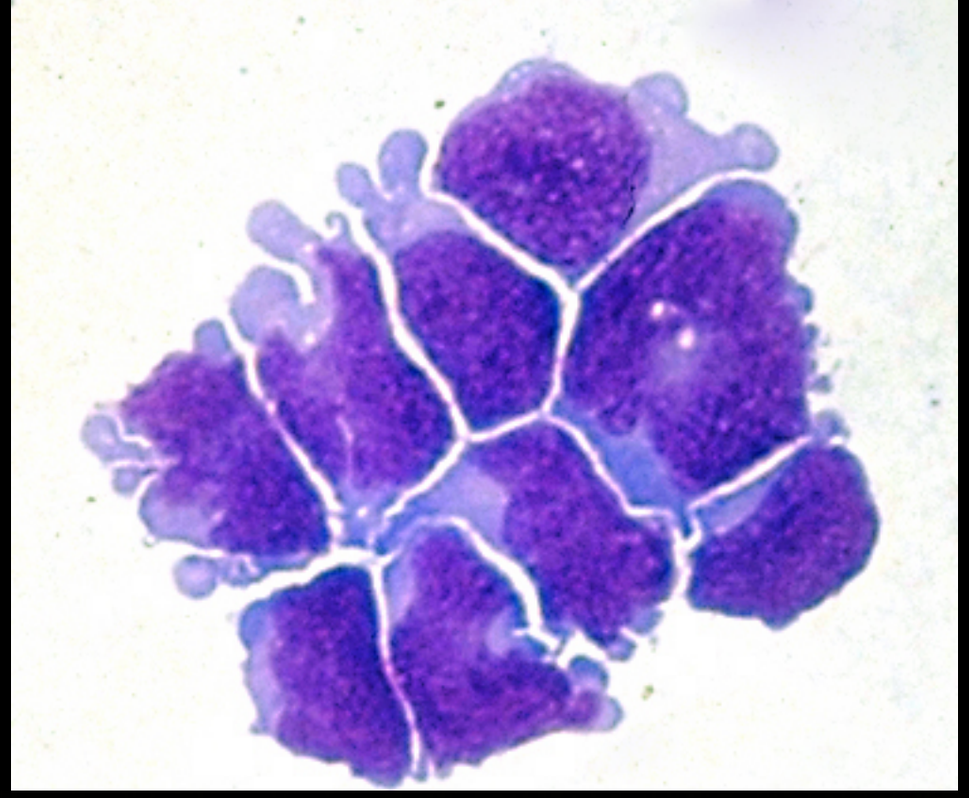

MEDULOBLASTOMA DE LA MEDULA ESPINAL

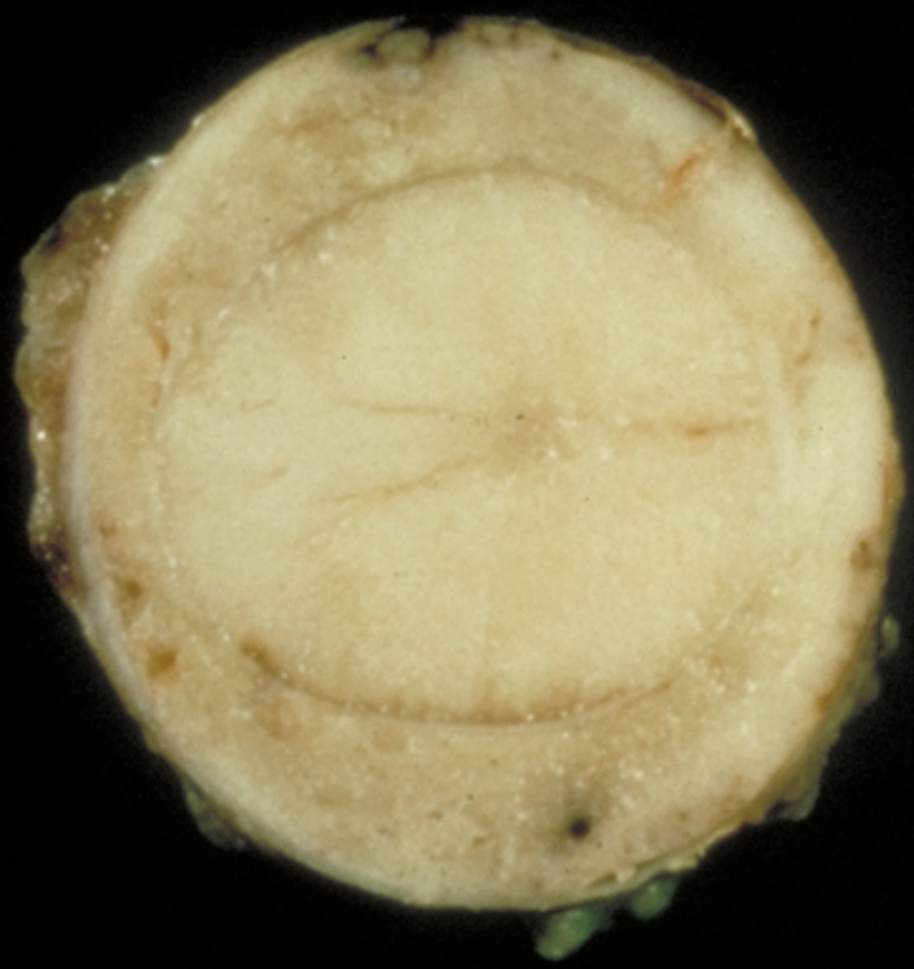

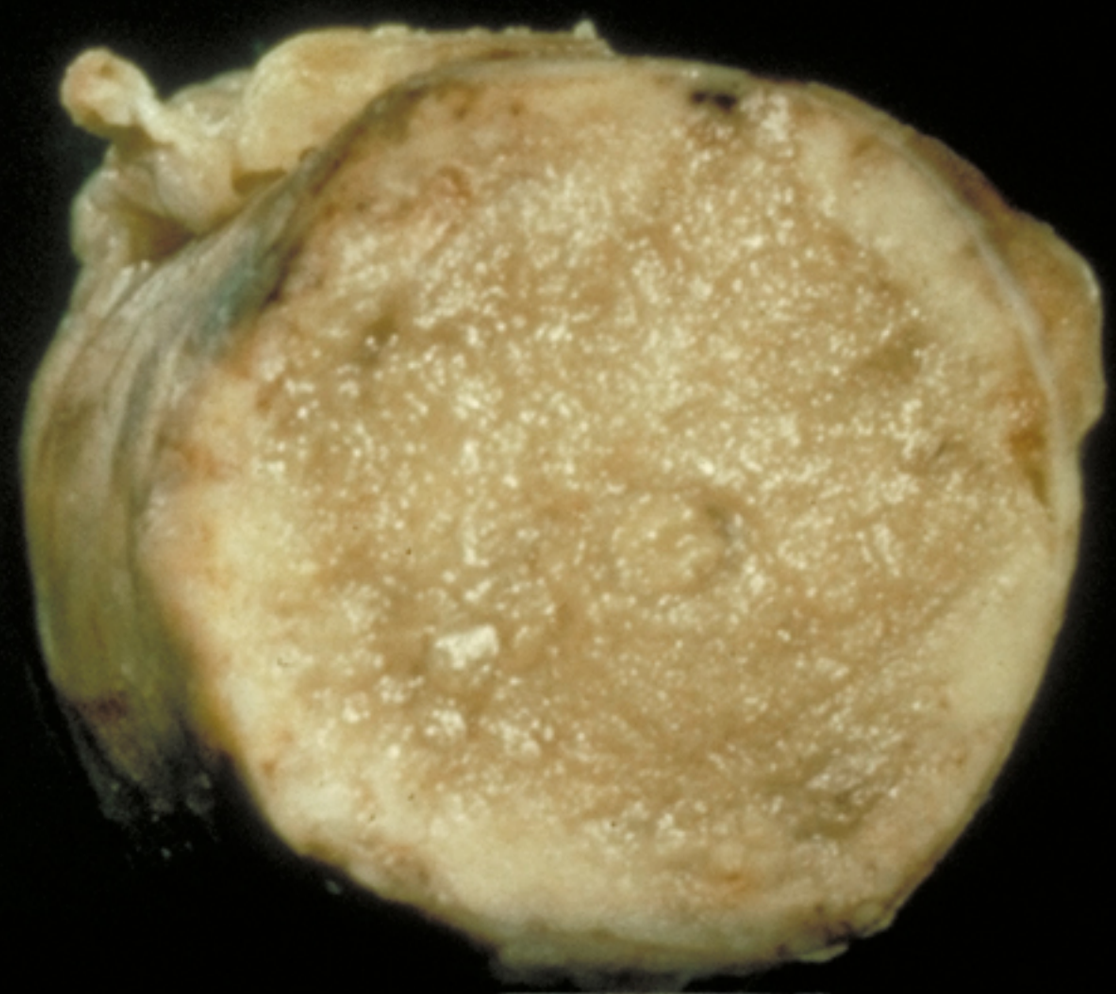

TUMOR NEUROECTODÉRMICO PRIMITIVO SUPRATENTORIAL

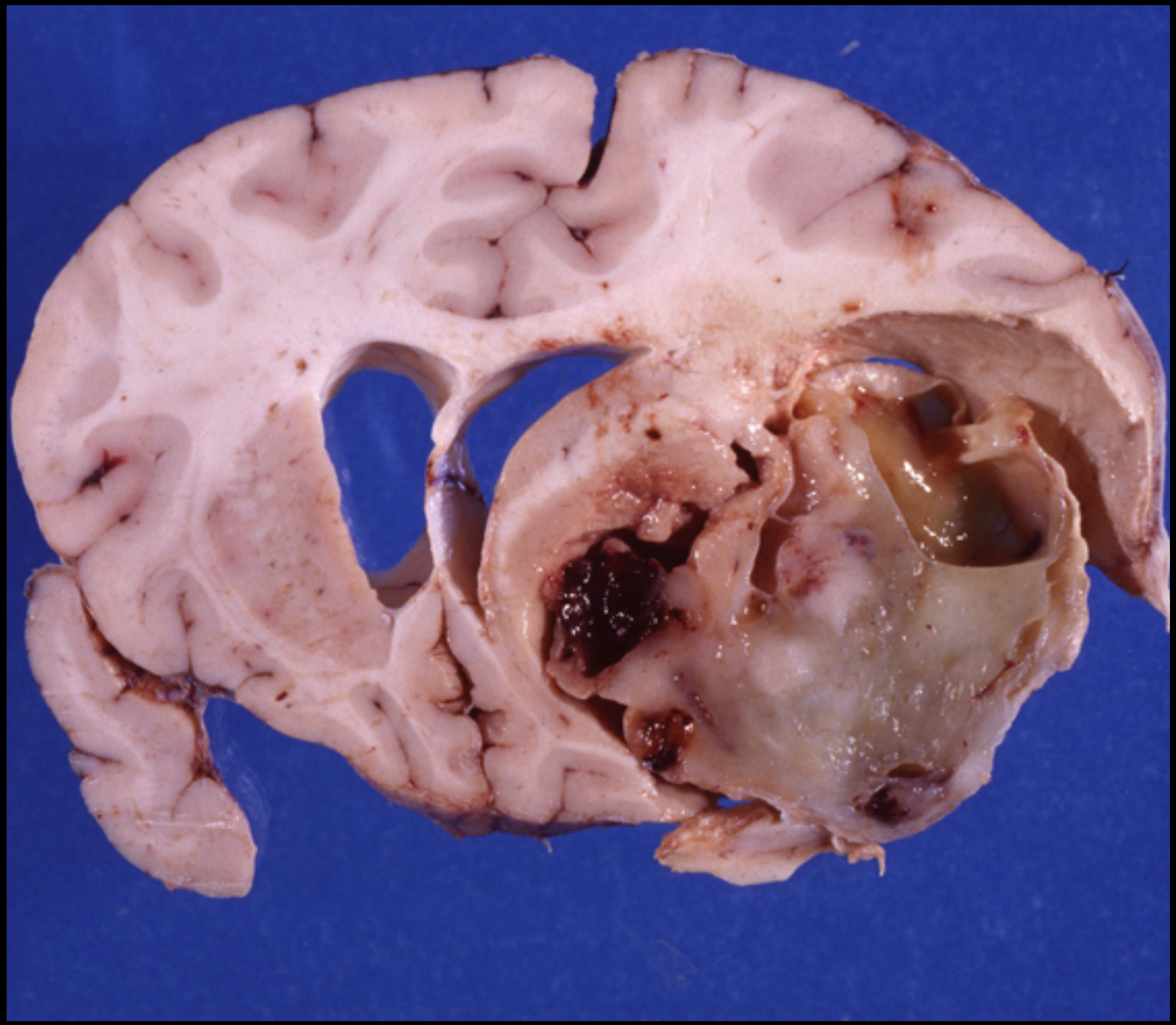

TUMOR TERATOIDE RABDOIDE ATIPICO

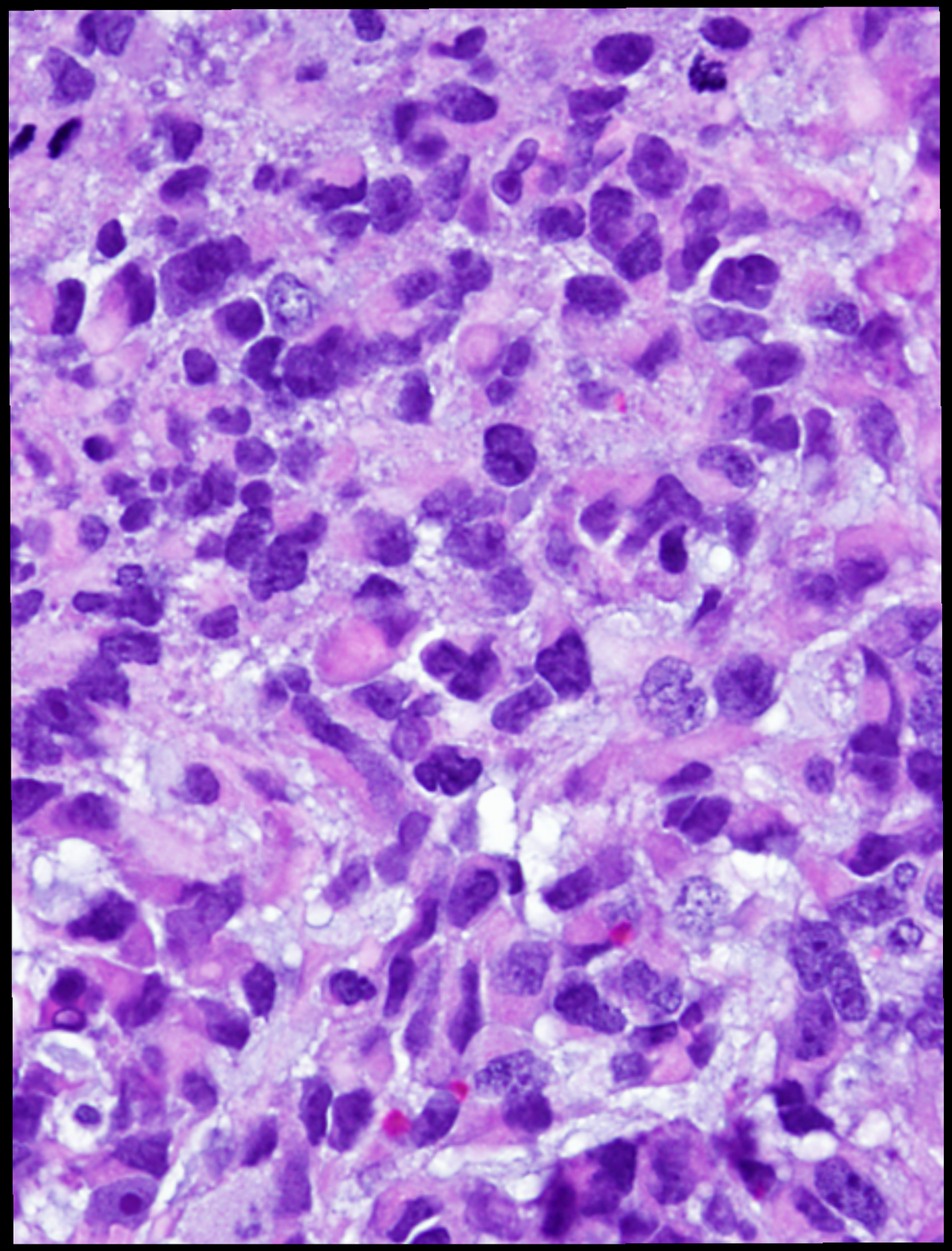

Tumor rabdoide teratoide atípico (ATRT), neoplasia altamente agresiva que afecta a niños muy pequeños. Afecta cerebelo (Hay ubicaciones extracerebelosas). Compuesta por células rabdoides y otros diversos elementos neuroectodermales y mesenquimales, de ahí el término teratoide.

Firma molecular distinta compartida por tumores rabdoides extraneurales, es decir, pérdida de ambas copias del gen INI1, ubicado en 22q11.3.

El producto de este gen está involucrado en la remodelación de la cromatina. En la tinción inmunohistoquímica, INI1 está ausente en los núcleos tumorales y presente en los núcleos no neoplásicos.

La pérdida de una copia de INI1 en la línea germinal da como resultado el Síndrome de Predisposición de Tumores Rabdoides, en el que los pacientes desarrollan tumores rabdoides renales y extrarrenales, incluidos ATRT y tumores del plexo coroideo.

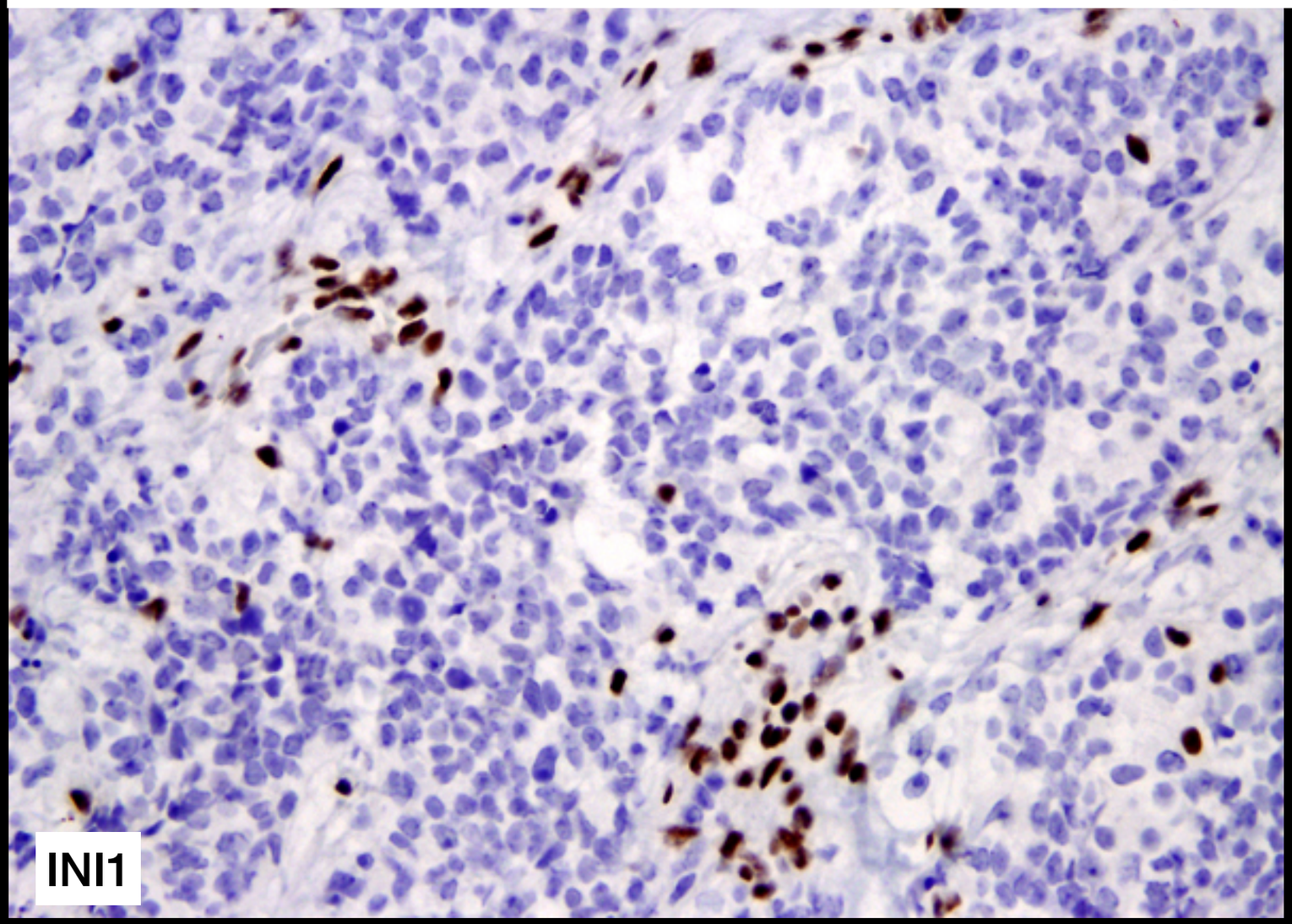

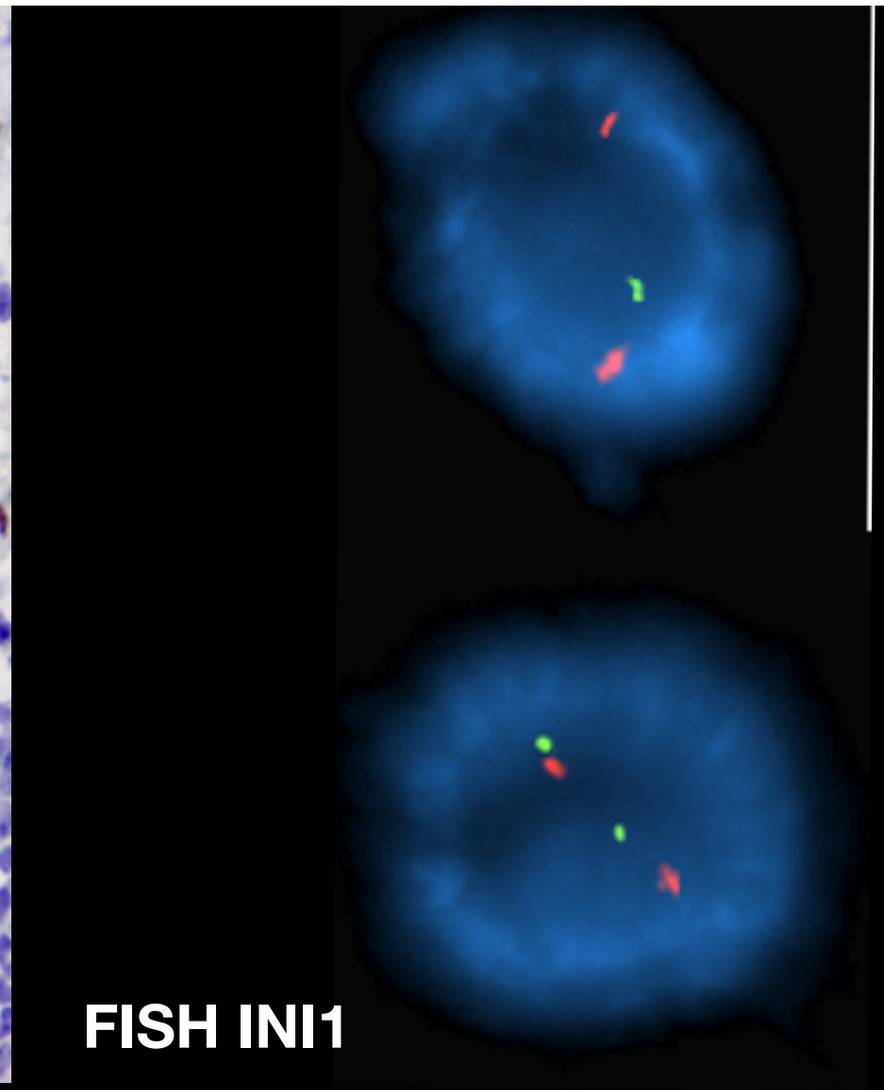

MENINGIOMA

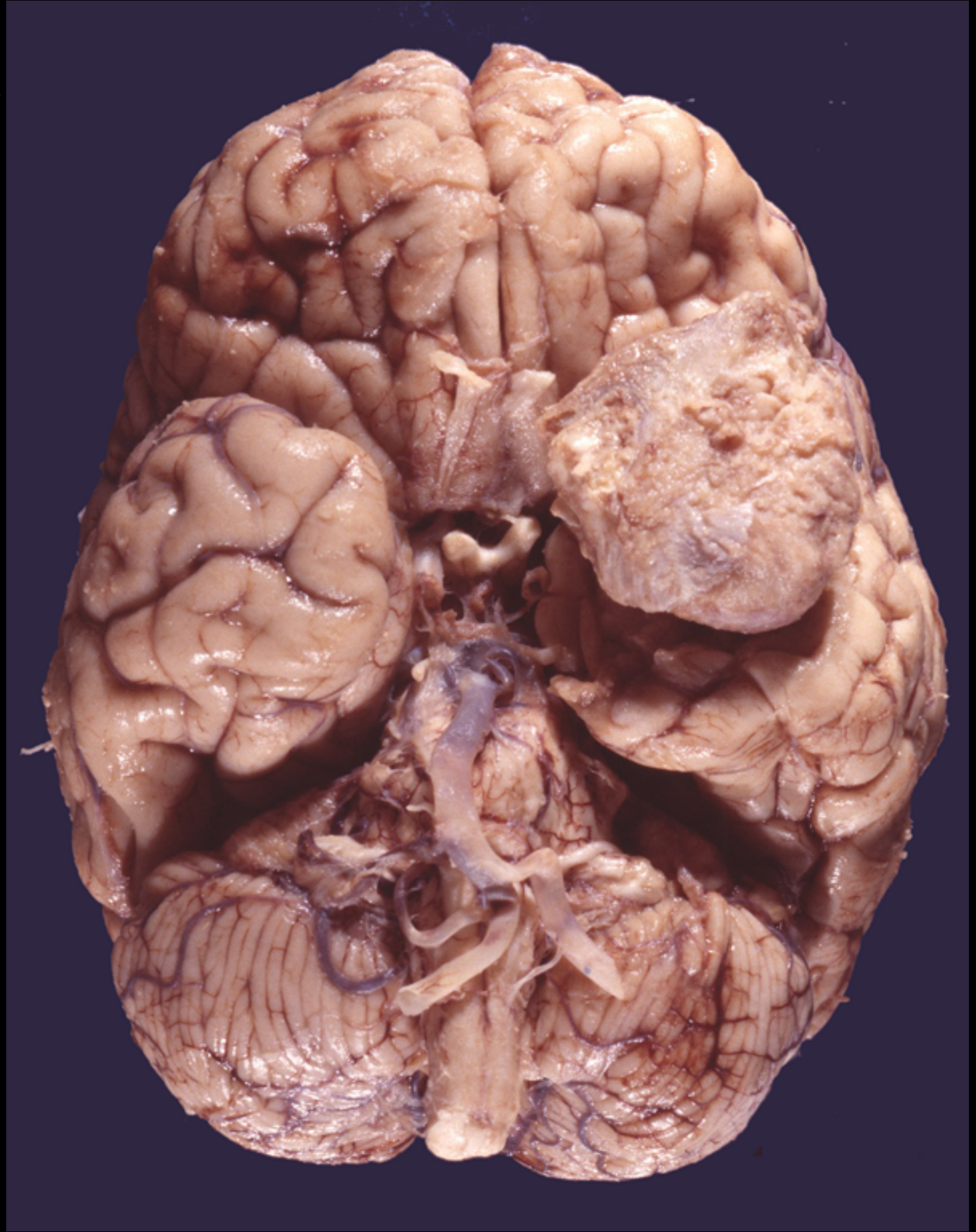

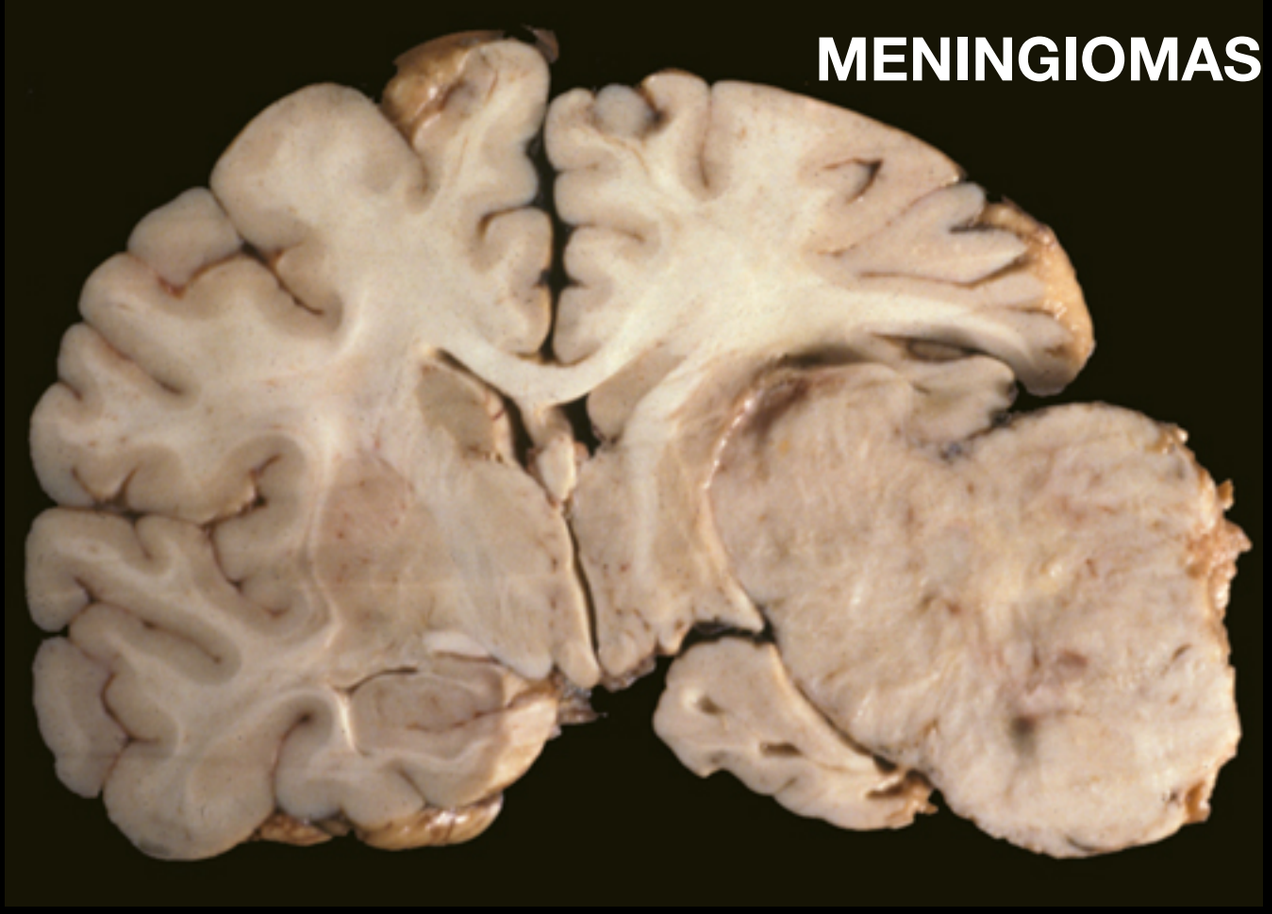
MENINGIOMAS

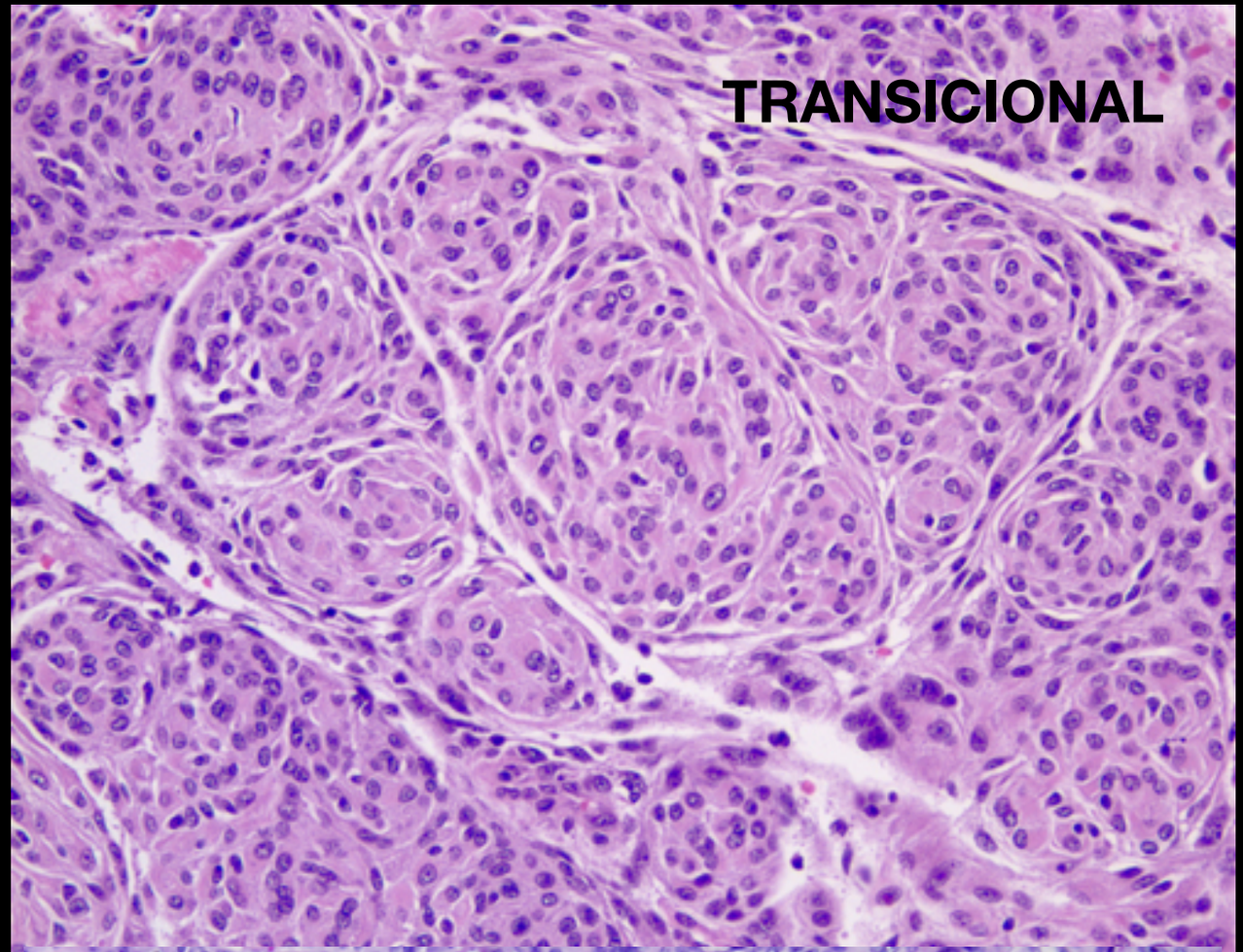
TRANSICIONAL

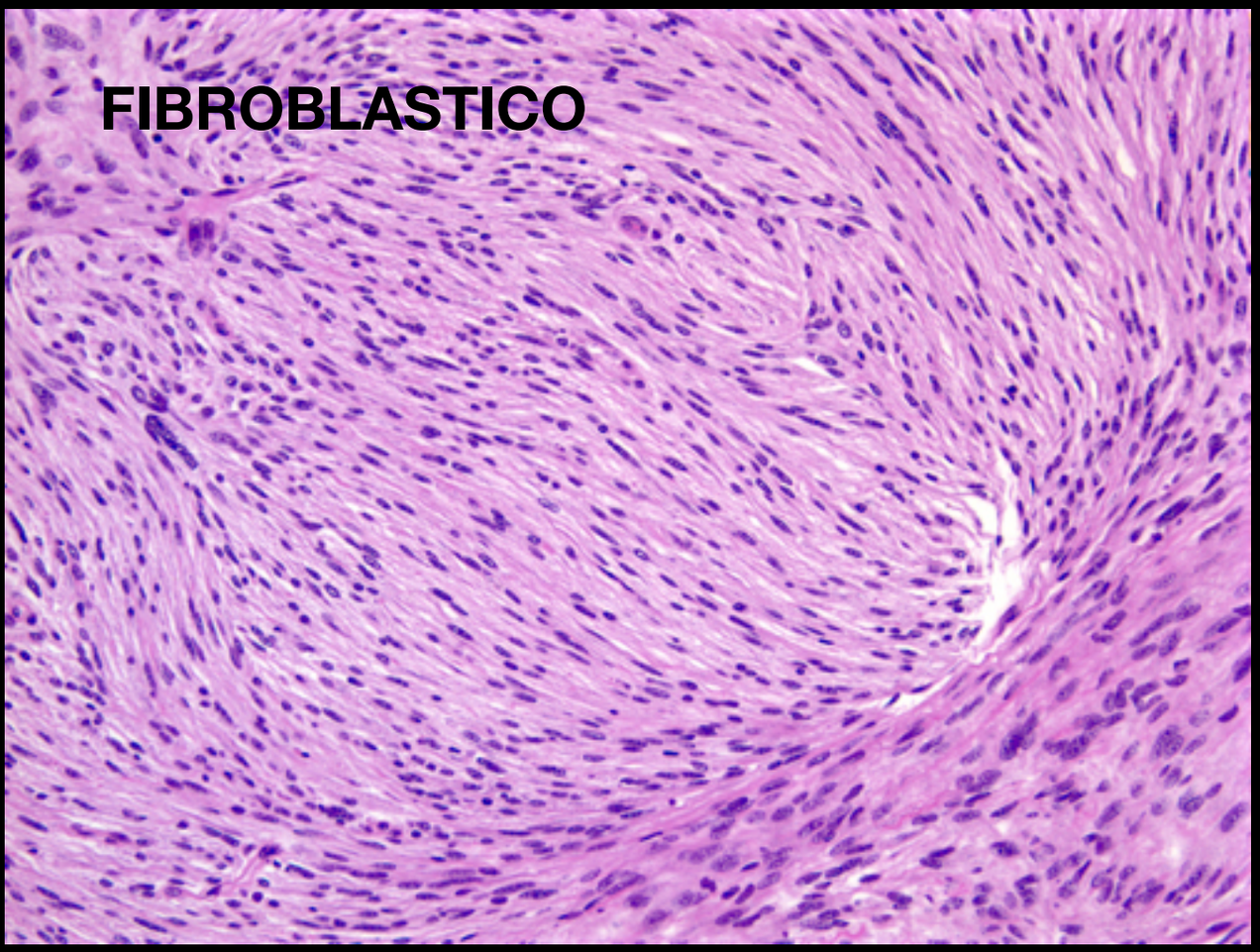
FIBROBLASTICO

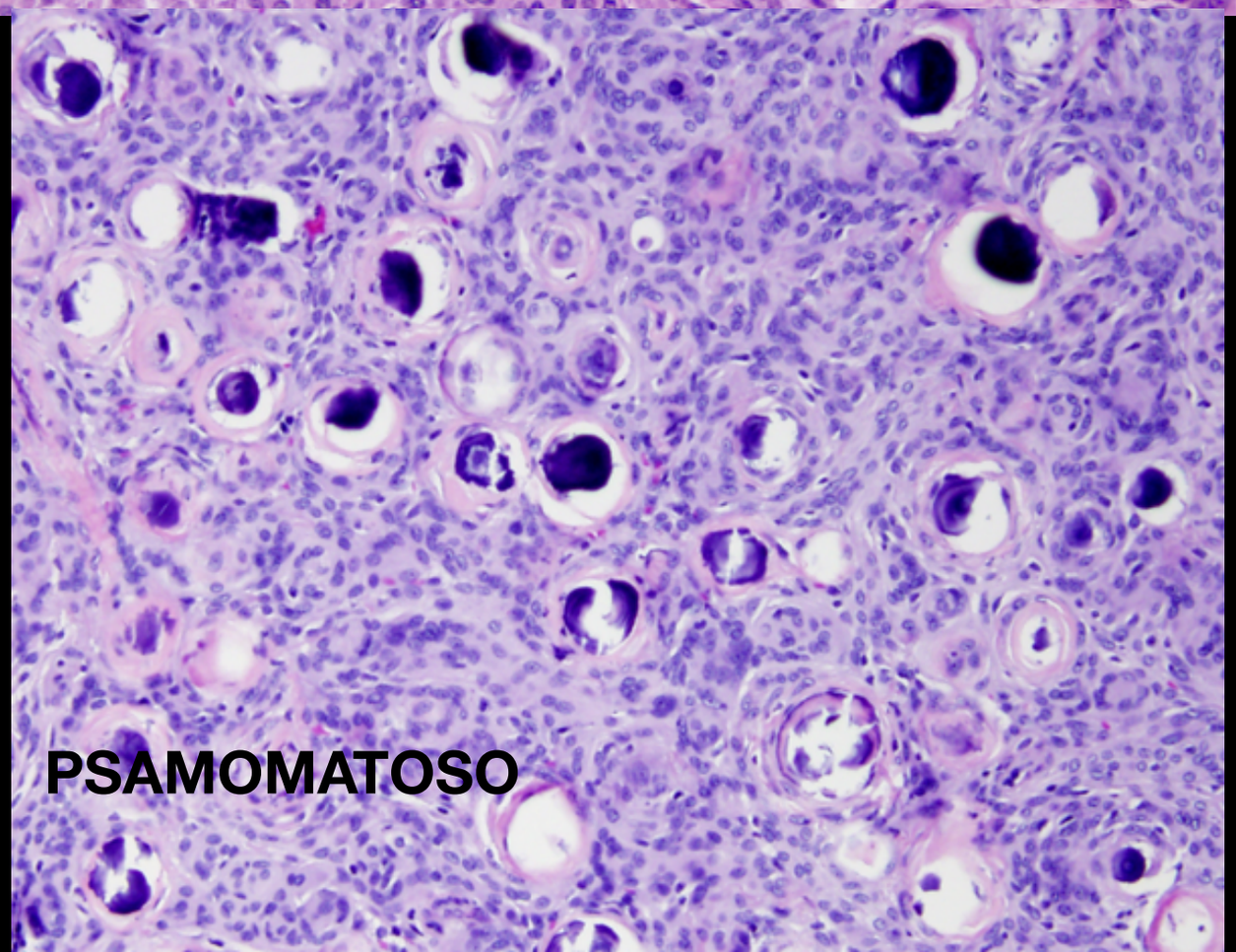
PSAMOMATOSO

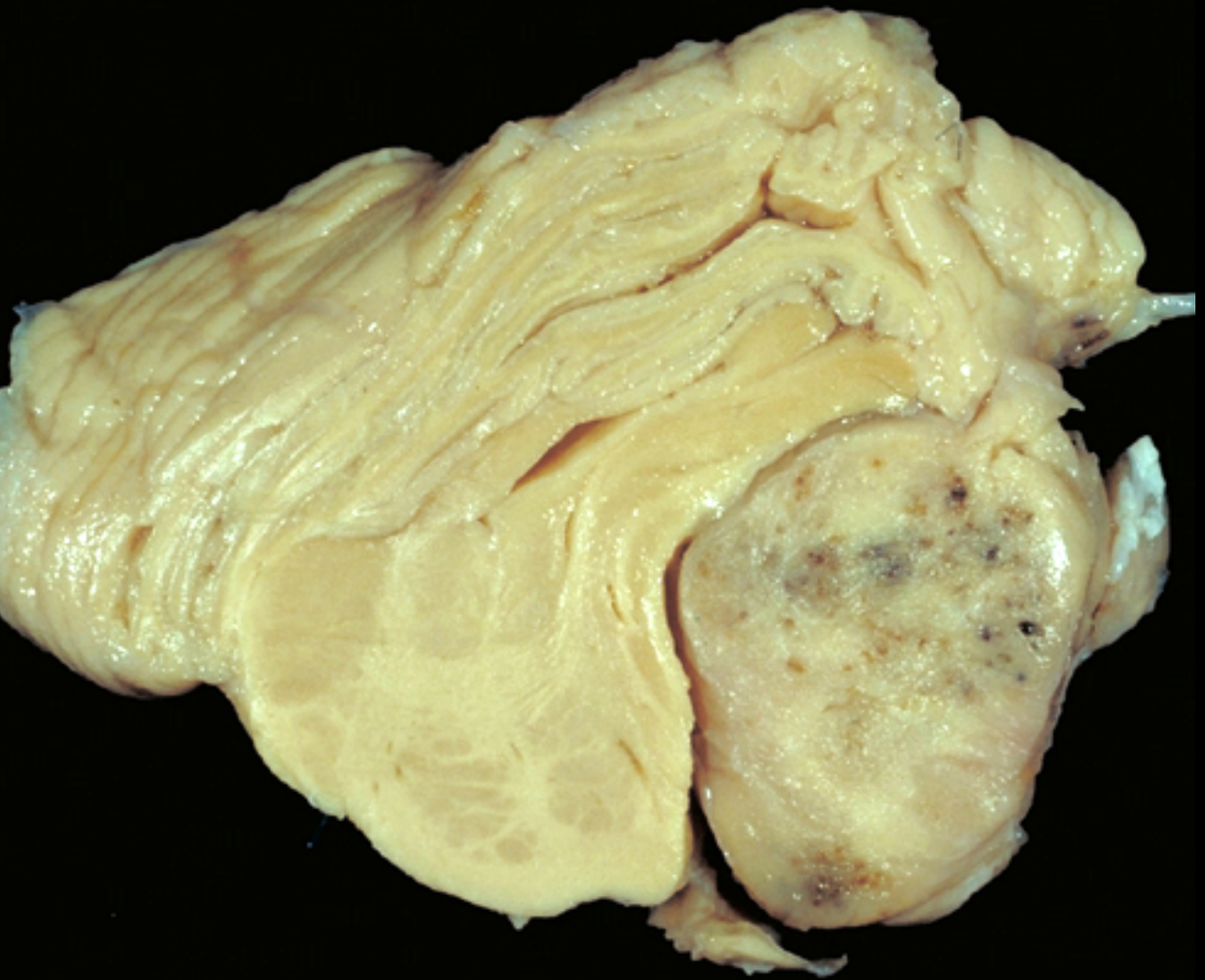

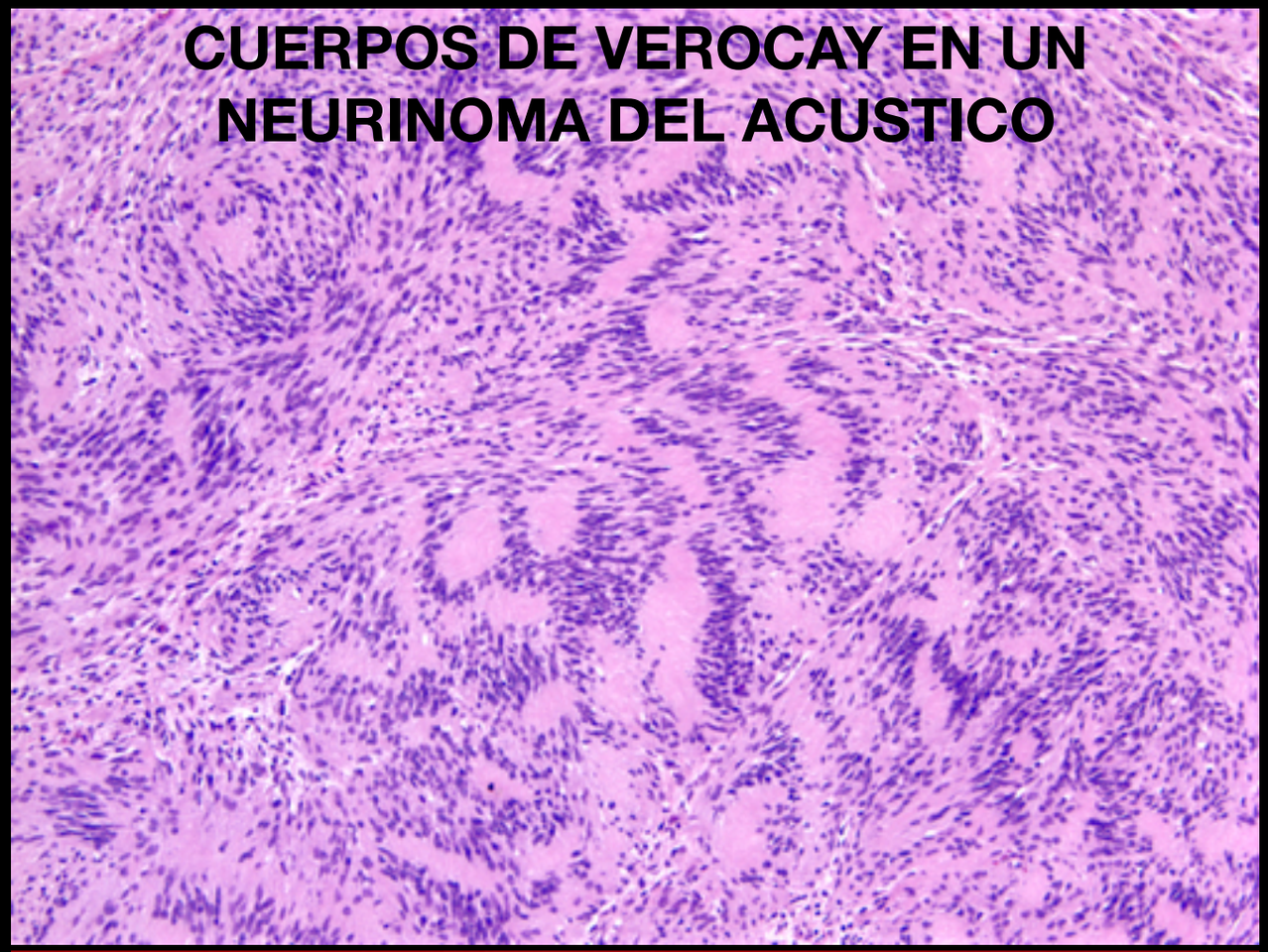
CUERPOS DE VEROCAY EN UN
NEURINOMA DEL ACUSTICO

SHWANNOMA

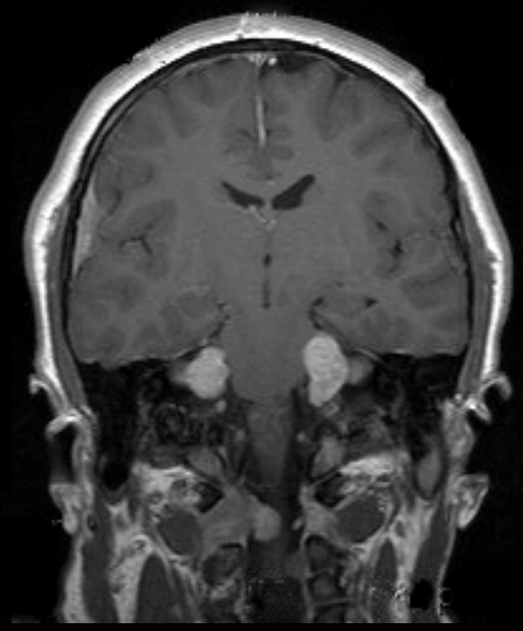

NEUROFIBROMA PLEXIFORME

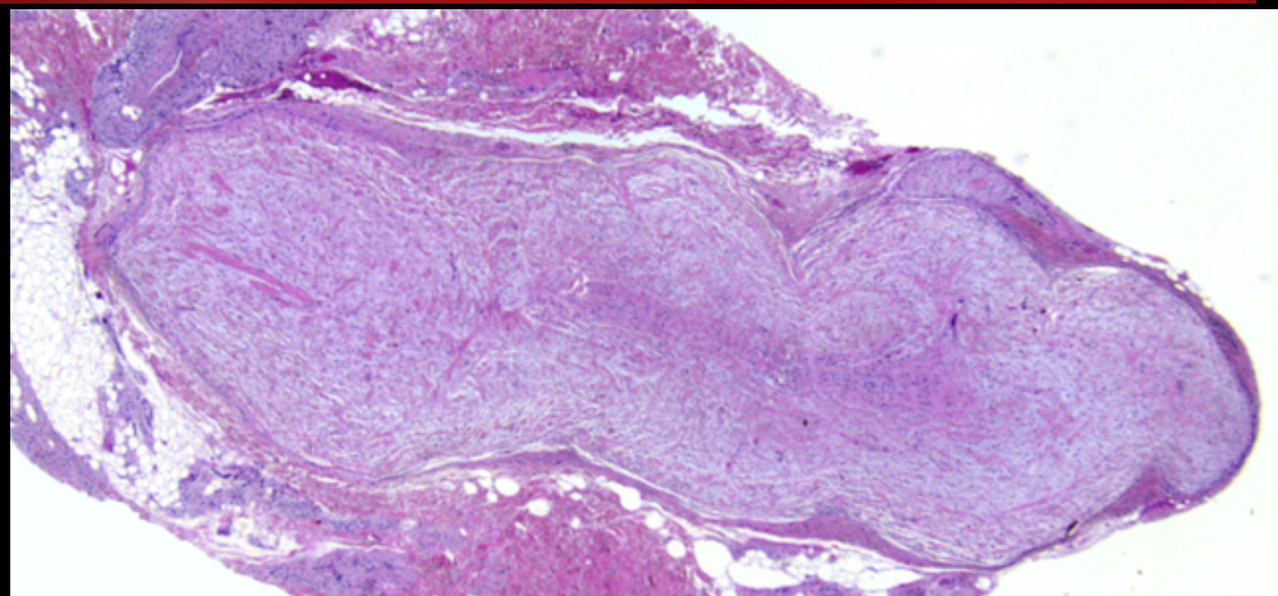

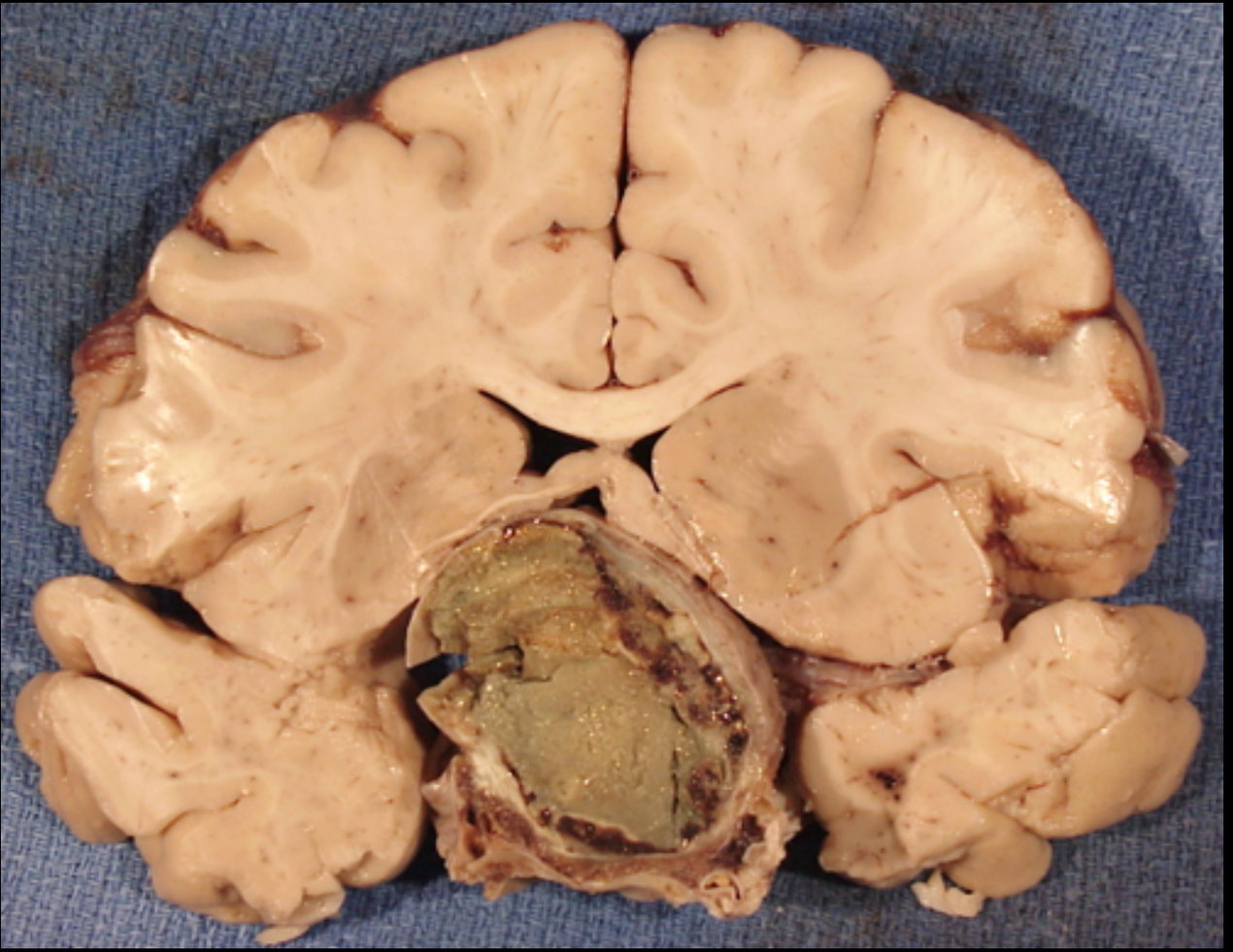

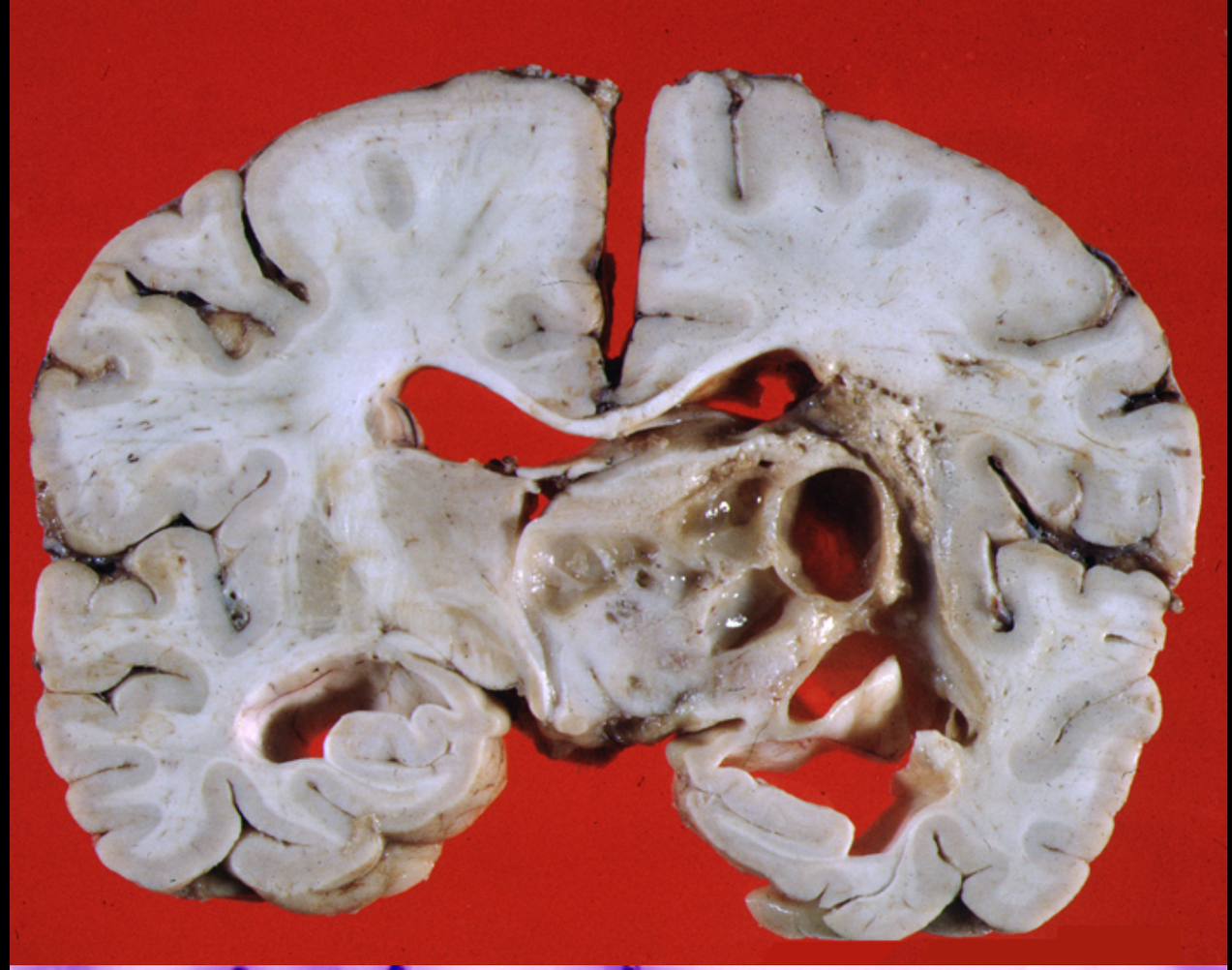

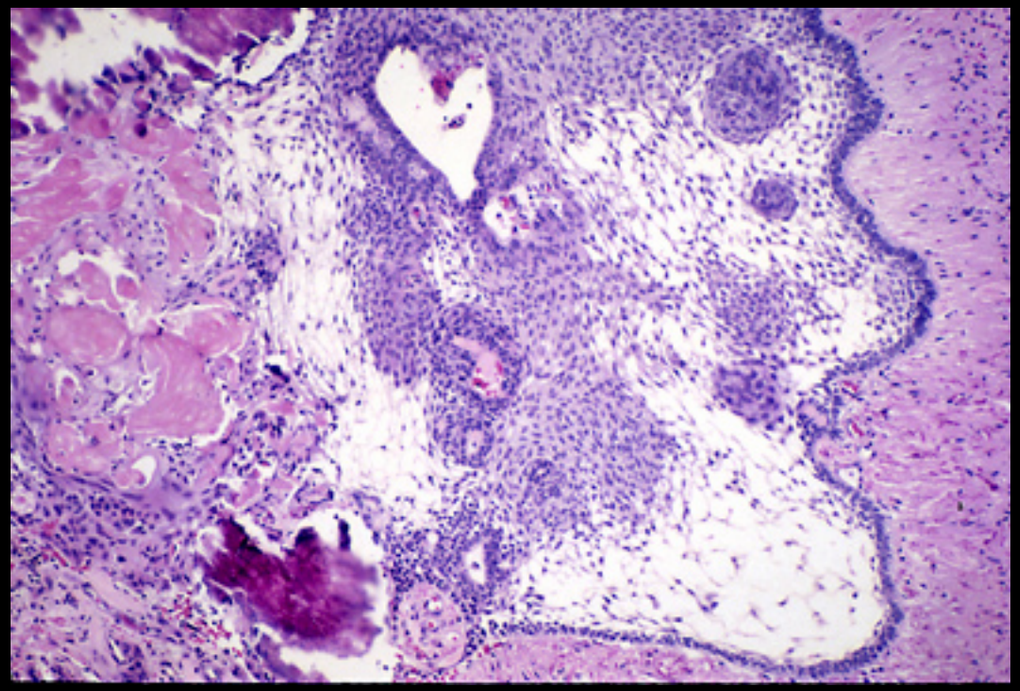



CRANEOFARINGIOMA

HEMANGIOBLASTOMA

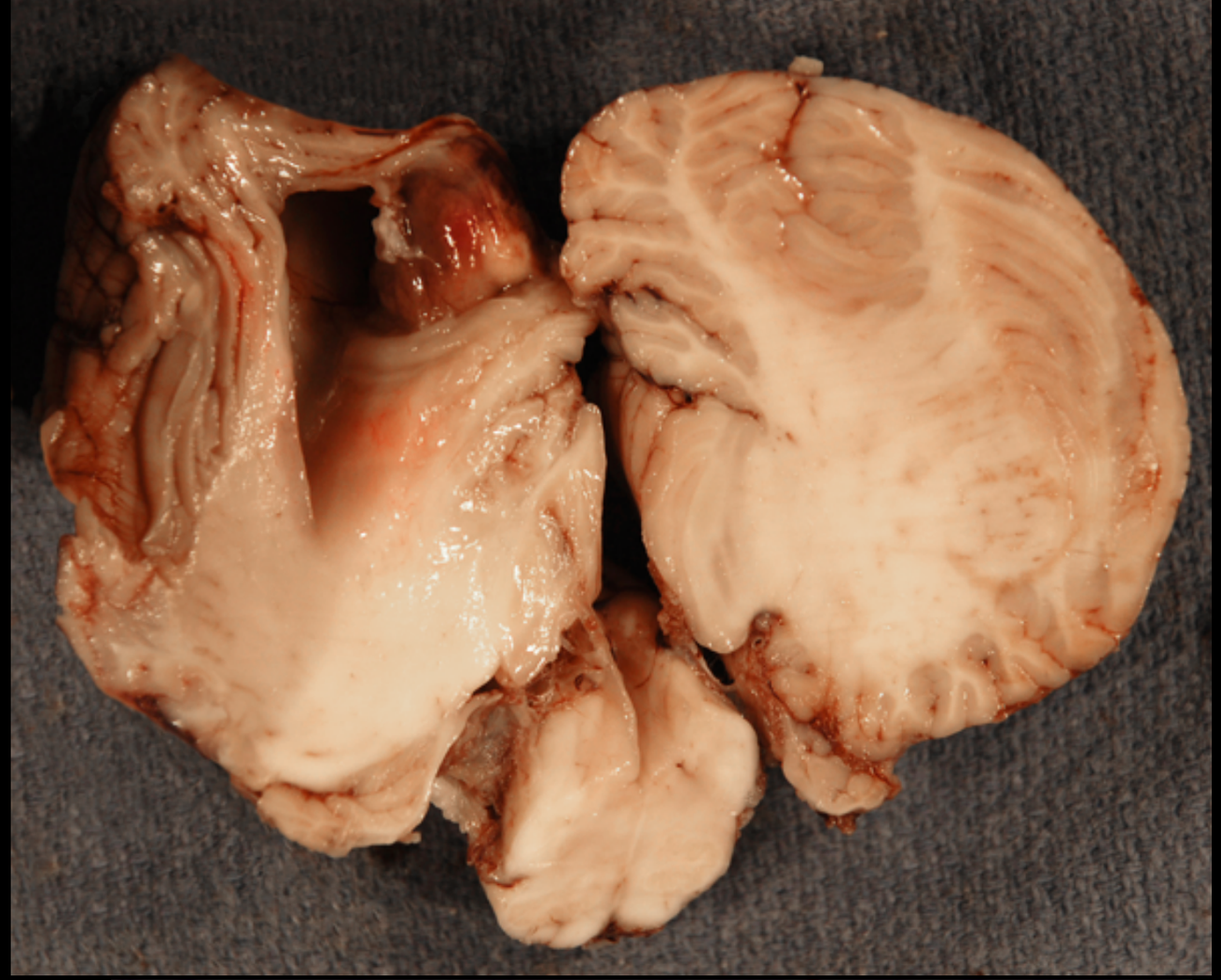

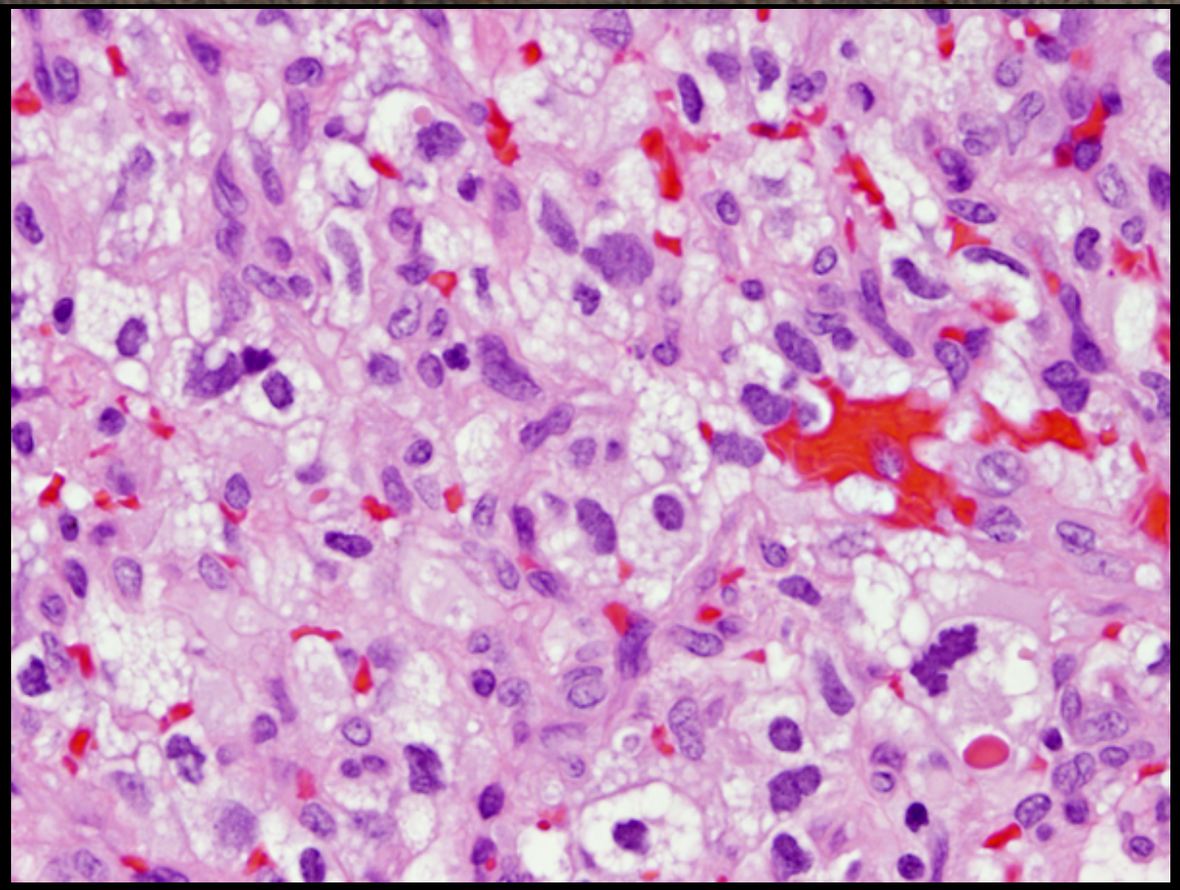

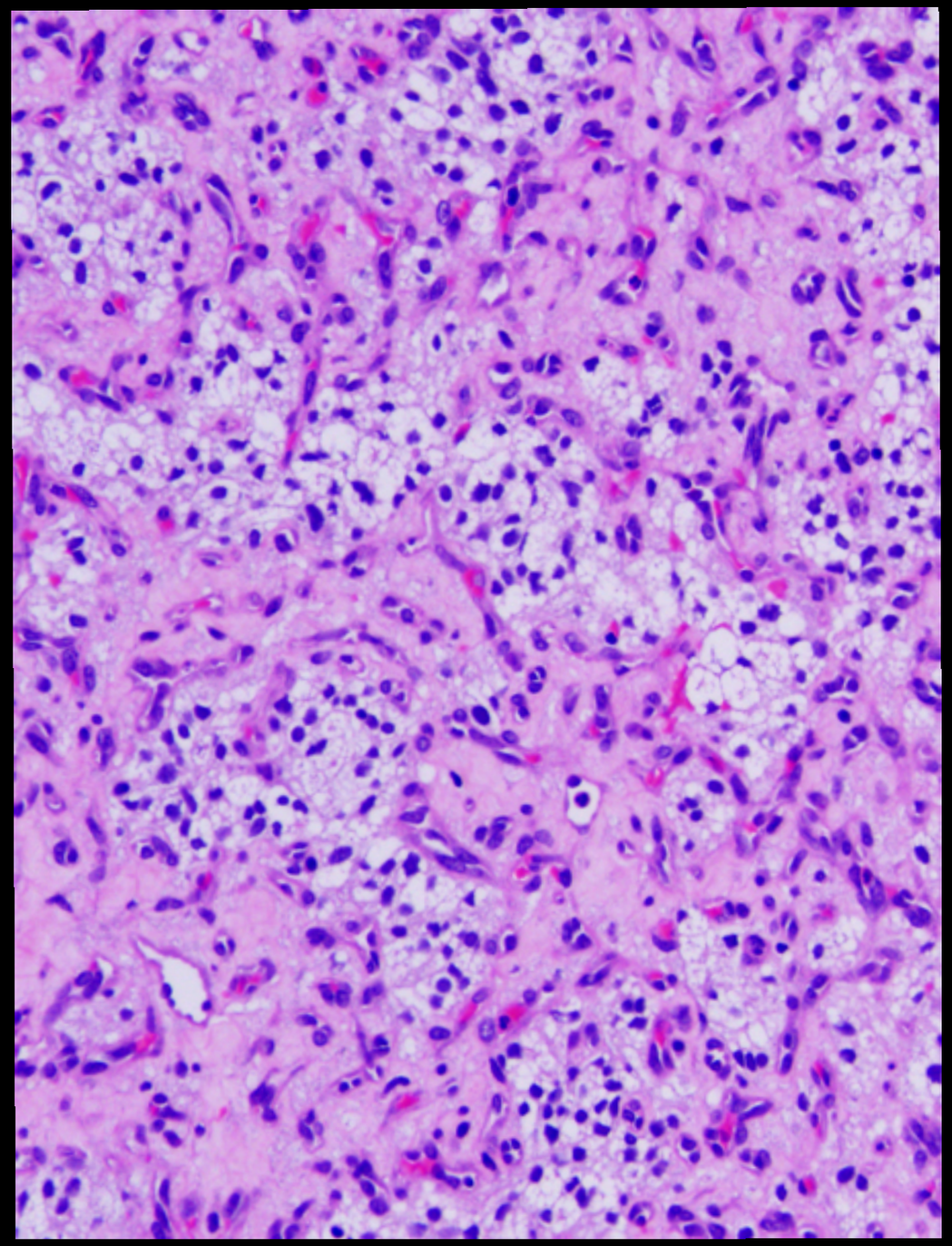

LINFOMA

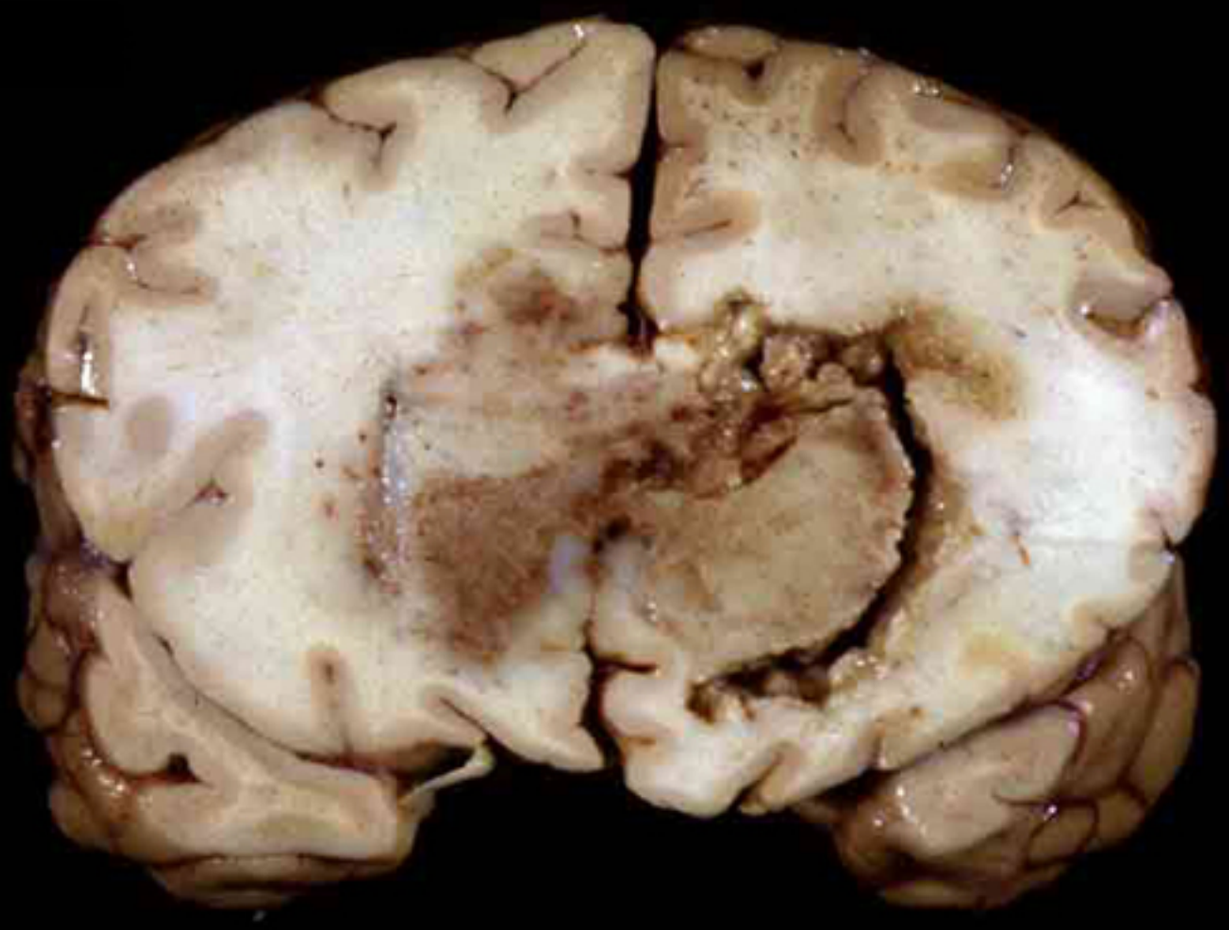

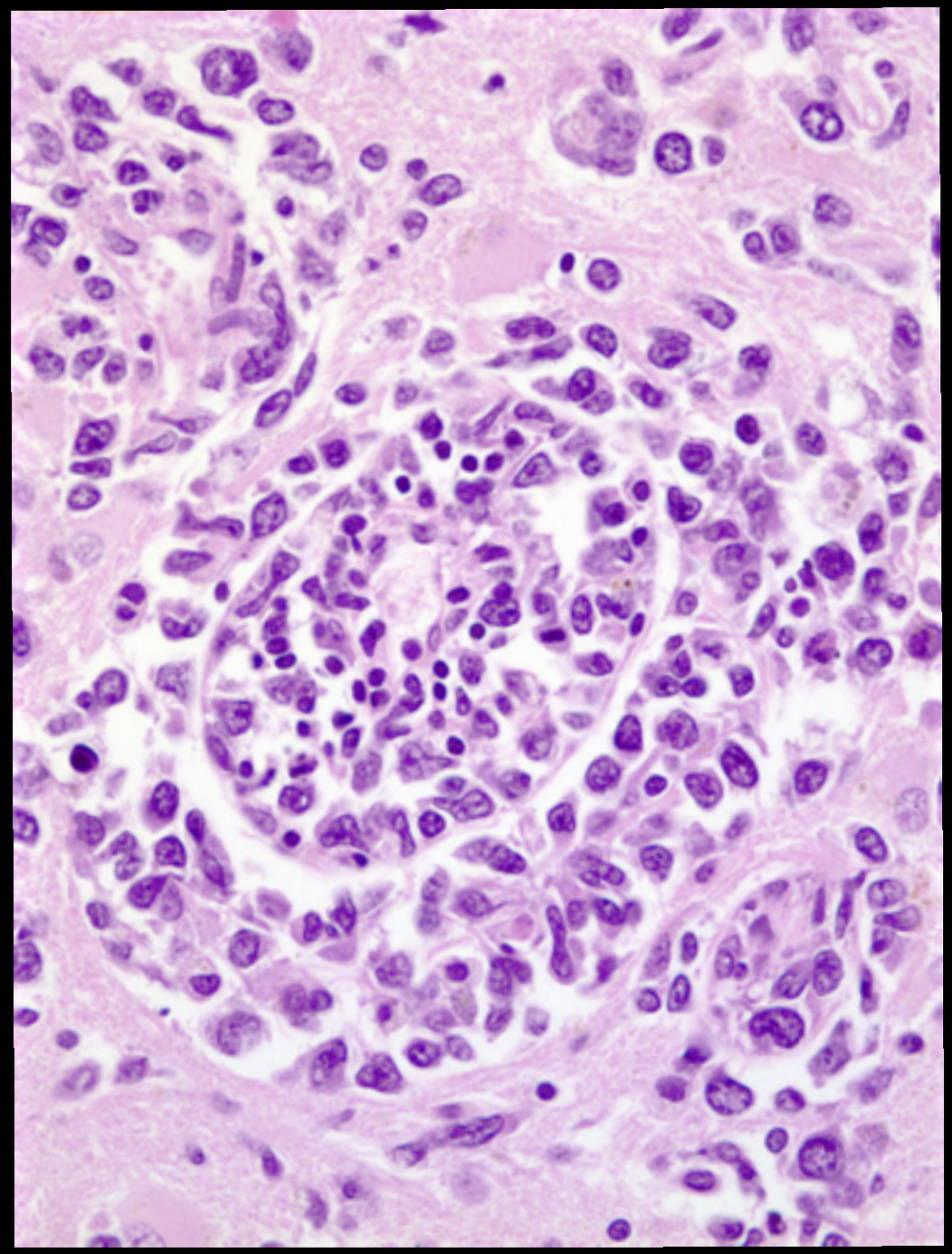

COMUN EN CUERPO CALLOSO
MANGUITOS PERIVASCULARES DE CÉLULAS NEOPLÁSICAS

CARCINOMATOSIS MENINGEA

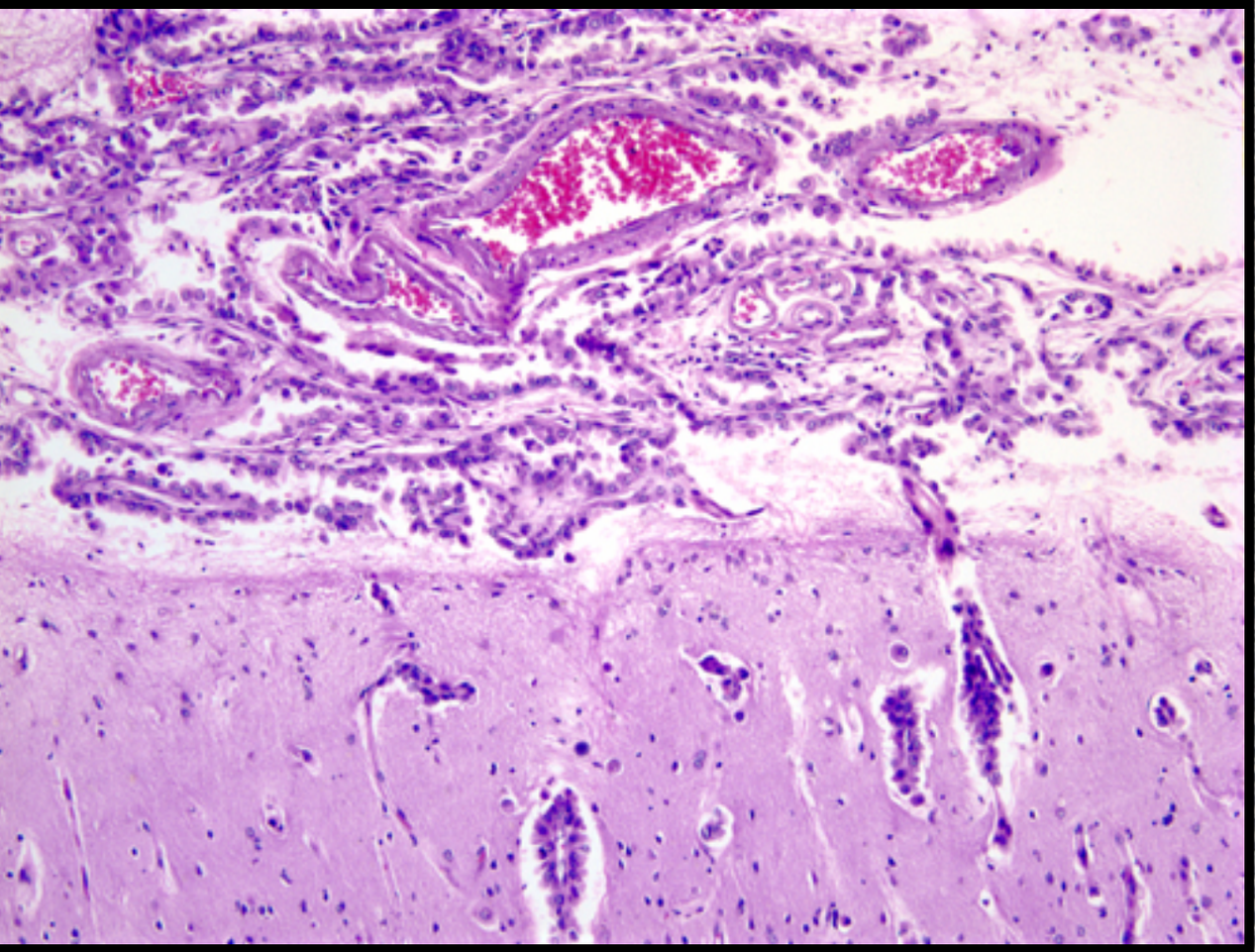

METÁSTASIS (COMUN EDEMA PERILESIONAL)

Tumores del sistema nervioso

Meduloblastoma

Tumor infantil a veces congénito
Sólo afecta al cerebelo
Maligno, aunque con supervivencias del 80% a los 5 años
Macro: en línea media
- Bien delimitado
- Color gris y consistencia blanda

Micro: células redondas que forman rosetas

Meningiomas

La mayoría benignos
Originados en la aracnoides
Macro: masas redondeadas y duras con tendencia a adherirse al hueso
Micro: células fusiformes **(fibroblástico)**, que forman sincitios **(sincitial)**, con células que recuerdan el epitelio de transición **(transicional)**, con cuerpos de psammoma **(psammomatoso)**, con vacuolas PAS+ (secretor)
Hay meningiomas anaplásicos de conducta muy agresiva, capaces de metastatizar

Linfomas

2% de los linfomas extranodales
Frecuentes en pacientes inmunodeficientes
Generalmente linfomas de células grandes B

Tumores de células germinales

Localizados en la línea media, especialmente en la glándula pineal
Los mismos tumores que aparecen en el testículo
- Teratoma, seminoma, carcinoma embrionario...

Metástasis

Principalmente carcinomas de pulmón, mama, melanoma, riñón y tracto gastrointestinal

Aspectos generales

Incidencia: 10-17/100.000 personas
La mitad primitivos y el otro 50% metastásicos
Todo tumor intracraneal es potencialmente maligno
Patrón de diseminación: a través del líquido cefalorraquídeo (LCR)
- Sólo metastatizan fuera del cerebro, después de la resección quirúrgica

Gliomas

Astrocitoma

Macro: tumor infiltrante, mal delimitado, de color gris
- Superficie de corte gelatinosa
- Frecuentes quistes

Micro: aumento de células con polimorfismo variable
- Citoplasma amplio con prolongaciones finas **(astrocitoma fibrilar)**
- Células con citoplasma amplio vacuolado **(astrocitoma protoplasmático)**
- Células con amplio citoplasma eosinófilo **(astrocitoma gemistocítico)**
- Células fusiformes mezcladas con fibras de Rosenthal **(astrocitoma pilocítico)**
- Anaplasia variable
- IHQ: GFAP+

Cuatro grados:
- Grado I: astrocitoma pilocítico
- Grado II: aumento de células iguales
- Grado III: anaplasia nuclear, mitosis, sin necrosis
- Grado IV **(glioblastoma multiforme)**: anaplasia y mitosis
  - Proliferación vascular
  - Necrosis

Oligodendroglioma

5-15% de los gliomas en individuos en la 4.ª-5.ª década
Sustancia blanca
Mejor pronóstico los que tienen la t(1;19)(q10;p10)
Macro: tumores infiltrantes con quistes, hemorragias y microcalcificaciones
Micro: células redondas con citoplasma claro («en huevo frito»)
- Delicada red vascular
- Calcificaciones en el 90% de los casos
- Mitosis, necrosis y anaplasia en los de mayor grado **(oligodendroglioma anaplásico)**

Ependimoma

En el sistema ventricular y el canal central de la médula ósea
5-10% de los tumores cerebrales
Células con núcleos redondos con fondo fibrilar
Forman rosetas y seudorrosetas (alrededor de vasos)
Algunos forman papilas con fondo mixoide **(ependimoma mixopapilar)**
Hay tambien **ependimomas anaplásicos**

Tumores neuronales

Neurocitoma central:
- Situado en el sistema ventricular
- Núcleos uniformes, redondos con islas de neurópilos
- Diagnóstico diferencial con el oligodendroglioma

Gangliogliomas
- Mezcla de células gliales y neuronas maduras

Tumor neuroepitelial disembrioplásico
- Tumor de bajo grado que afecta a niños
- Lóbulo temporal
- Células redondas y neuronas en columnas alrededor de la lesión
- Nódulos mixoides